

Balanite Sifilítica de Follmann: Armadilhas de Laboratório

Filipa Tavares Almeida¹, Filomena Azevedo², Carmen Lisboa^{2,3} 

¹Department of Dermatology and Venereology, Hospital de Braga, Braga, Portugal

²Department of Dermatology and Venereology, Centro Hospitalar Universitário São João, Porto, Portugal

³Division of Microbiology, Department of Pathology, Faculty of Medicine, University of Porto, Portugal; CINTESIS - Center for Health Technology and Services Research, Faculty of Medicine of the University of Porto, Portugal

RESUMO – Descreve-se um caso de sífilis recente, num doente com infeção VIH e história prévia de sífilis, caracterizado por balanite e sífilides papulares, e um resultado falso negativo para o teste VDRL devido ao fenómeno de prozona. Este resultado falso negativo decorre de títulos muito elevados de anticorpos, que interferem na formação de complexos antigénio-anticorpo, necessários para visualizar um teste de floculação positivo.

PALAVRAS-CHAVE – Balanite/diagnóstico; Sífilis/diagnóstico.

Syphilitic Balanitis of Follmann: Laboratory Pitfalls

ABSTRACT – We report a case of early syphilis, presenting as balanitis and papular syphilides in an HIV-infected patient, with a previous history of syphilis infection, which demonstrated a false negative VDRL testing due to a prozone phenomenon. This false negative response results from overwhelming antibody titers, which interfere with the proper formation of the antigen-antibody lattice network, necessary to visualize a positive flocculation test.

KEYWORDS – Keywords: Balanitis/diagnosis; Syphilis/diagnosis.

INTRODUCTION

Diagnosis of syphilis remains a major challenge due to its multiple clinical presentations, and confirmation of diagnosis is still based mostly on serological testing, although several limitations have been described. Prozone phenomenon is responsible for false negative non-treponemal syphilis testing, which can be more frequent in cases with HIV/syphilis coinfection.¹ In patients with a history of syphilis in the past, the diagnosis of syphilis reinfection is difficult if prozone phenomenon occurs.

CASE REPORT

A 46-year-old male patient, MSM (man who has sex with man) was referred to our department due to balanitis present for 4 weeks. The patient had HIV-1 infection diagnosed in 2010, with good adherence to HAART (highly active antiretroviral therapy) and >600 CD4+ cells/ μ L and an undetectable viral load at the examination. He also had a

history of latent syphilis in 2009, with the last serologic test reactive for TPPA (*Treponema pallidum* particle agglutination assay) 1 year before. He also suffered from recurrent genital herpes for 10 years. The patient reported only one sexual partner in the last year and his last sexual encounter was 3 months ago.

Physical examination revealed balanoposthitis with an erythematous eroded plaque on the balanopreputial sulcus, with a firm base on palpation, consistent with the syphilitic balanitis of Follmann (Fig. 1), associated with a painless unilateral inguinal lymphadenopathy.

A thorough examination also revealed asymptomatic erythematous papules and nodules with slight scaling, dispersed through the trunk, upper arms, forehead and right foot (Figs 2a and 2b), that appeared after the genital lesion.

He also referred headache, muscle pain, and fatigue, that faded away without treatment. He had no lesions on the oral mucosa or perianal region.

Correspondência: Filipa Tavares Almeida

R. das Comunidades Lusíadas 133

4710-243 Braga, Portugal

E-mail: filipa.almeida6@hotmail.com

DOI: <https://dx.doi.org/10.29021/spdv.78.3.1199>

Recebido/Received
2020/04/21

Aceite/Accepted
2020/07/01

Publicado/Published
2020/09/30

© Autor (es) (ou seu (s) empregador (es)) 2020 Revista SPDV. Reutilização permitida de acordo com CC BY-NC. Nenhuma reutilização comercial.

© Author(s) (or their employer(s)) 2020 SPDV Journal. Re-use permitted under CC BY-NC. No commercial re-use.

Caso Clínico

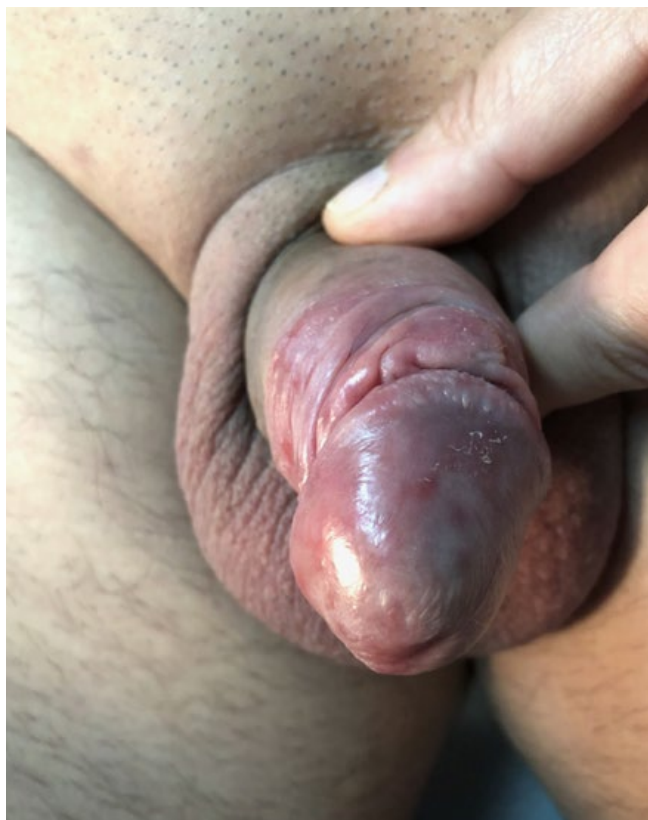

Figure 1 - Balanoposthitis and eroded plaque on the balanopreputial sulcus.

At the time of the consultation, he had a reactive TPPA and negative VDRL, and PCR (polymerase chain reaction) testing performed on the eroded penis lesion was negative for *Treponema pallidum* and herpes simplex virus type 1 and 2. Despite these laboratorial findings, as there was a high clinical suspicion of syphilis, it was decided to repeat the serological tests for syphilis, to complete the screening for sexually transmitted infections, perform a lesional biopsy and a new genital scraping for PCR testing and initiate immediately treatment with long acting benzathine penicillin G (three doses of 2.4 million units intramuscular each at 1-week intervals).

Serological tests for syphilis revealed a positive VDRL (1:32), but PCR testing was again negative for *T. pallidum*. The screening for other sexually transmitted infections was negative. Histopathology showed a lymphoplasmocytic mononuclear inflammatory infiltrate in the dermis, supporting the clinical diagnosis of syphilis.

A week after treatment the patient was feeling better with disappearance of almost all the lesions, and clearance was complete at 4 weeks.

CONCLUSION

This case reports a patient with syphilis reinfection presenting as a syphilitic balanitis of Follmann and syphilides on the trunk and limbs and a negative VDRL as a “prozone phenomenon”. The patient had a past history of syphilis, so a reactive TPPA test was expected. Actually, treponemal tests fail to distinguish treated syphilis from active/latent syphilis.

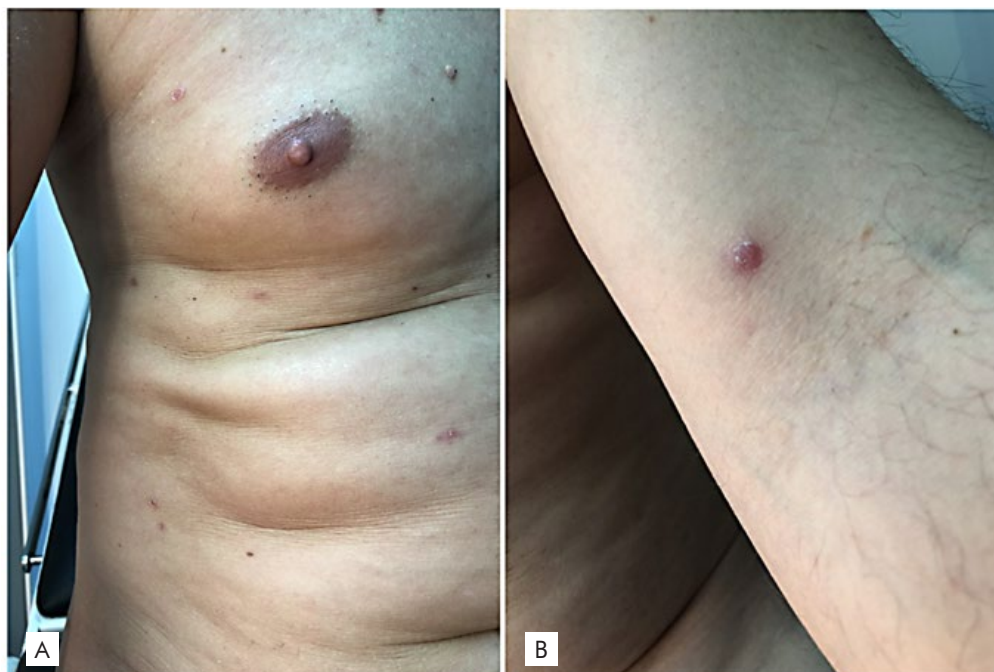

Figure 2 - Multiple isolated erythematous papules and nodules on the trunk (A) and left arm (B).

Prozone phenomenon is an immunological phenomenon responsible for false negative non-treponemal tests, such as VDRL. It occurs when there are extremely high levels of antibodies in patients with syphilis, which interfere with the formation of that lattice of antigen-antibody complexes necessary for visualization of flocculation,² precipitation or agglutination. Reaction will be positive when the optimal ratio of antigen to antibody yields an insoluble precipitate.³ The zone of equivalence defines this optimal ratio. In the zone of antibody excess (prozone) or antigen excess (postzone), false negative results may occur.⁴

The incidence of prozone phenomenon is estimated to be 0.2% - 2%,⁵ but it may be higher in HIV-positive population due to B-cell dysregulation leading to hyper-responsiveness to antigen stimulation and greater antibody production.⁶

Concerning syphilitic balanitis of Follmann, it is considered a very uncommon condition, given that the incidence of balanitis in cases of primary syphilis is reported to be 0.3% - 0.5%.⁷ Up to now, less than 100 cases has been described in literature and it remains unknown if it is more frequent in high risk groups, such as MSM and/or HIV-positive patients.⁸

PCR is a fast and efficient test for the detection of *T. pallidum* mostly in primary genital or anal chancres. In our case the PCR testing for *T. pallidum* was negative but this result must not exclude the diagnosis of syphilis. Actually, *T. pallidum* PCR seems to be more efficient to confirm than to exclude syphilis diagnosis.⁹

This case reminds that syphilis is, in fact, the great imitator, due to its clinical polymorphism, raising several differential diagnoses. Since prozone phenomenon may occur with tests frequently used for laboratory diagnosis of syphilis, it further increases the clinical challenge.

As *T. pallidum* specific serology generally remains reactive for life, the diagnosis of syphilis reinfection relies on clinical assessment and non-treponemal serologic testing.¹⁰ Given this, it is important that clinicians maintain a high index of suspicion, to consider this phenomenon in patients with clinical signs suggestive of syphilis, when the non-treponemal tests are negative.

Learning points

Syphilis diagnosis remains a major challenge and a complex diagnosis. Although several limitations have been described, serological testing remain the leading method for syphilis diagnosis.

Prozone phenomenon represents a false negativity of non-treponemal tests, such as VDRL, which occurs when there are extremely high levels of antibodies in patients with syphilis.

Conflitos de interesse: Os autores declaram a inexistência de conflitos de interesse na realização do presente trabalho.

Fontes de financiamento: Não existiram fontes externas de financiamento para a realização deste artigo.

Confidencialidade dos dados: Os autores declaram ter seguido os protocolos da sua instituição acerca da publicação dos dados de doentes.

Consentimento: Consentimento do doente para publicação obtido.

Proveniência e revisão por pares: Não comissionado; revisão externa por pares.


Conflicts of interest: The authors have no conflicts of interest to declare.

Financing support: This work has not received any contribution, grant or scholarship.

Confidentiality of data: The authors declare that they have followed the protocols of their work center on the publication of data from patients.

Patient Consent: Consent for publication was obtained.

Provenance and peer review: Not commissioned; externally peer reviewed

 ORCID

Filipa Tavares Almeida

<https://orcid.org/0000-0001-6561-5338>

Filomena Azevedo

<https://orcid.org/0000-0003-0402-6382>

Carmen Lisboa

<https://orcid.org/0000-0001-8247-8902>

REFERENCES

1. Vasconcelos P, Fraga A, Costa JB, Filipe P, Almeida LS, Marques MS. Fenómeno Prozona em Sífilis secundária. A importância da comunicação entre o clínico e o laboratório. *Rev Soc Port Dermatol Venereol.* 2012;70:113-6.
2. Battistella M, Le Cleach L, Lacert A, Perrin P. Extensive nodular secondary syphilis with prozone phenomenon. *Arch Dermatol.* 2008;144:1078-9. doi: 10.1001/archderm.144.8.1078.
3. Sidana R, Mangala HC, Murugesh SB, Ravindra K. Prozone phenomenon in secondary syphilis. *Indian J Sex Transm Dis AIDS.* 2011; 32: 47-49. doi: 10.4103/0253-7184.81256.
4. Bitencourt PT, Mariano PC, Castro CG, Paolini KS, Meotti CD, Franco LM. Fenómeno Prozona em paciente HIV negativo. *Rev Soc Port Dermatol Venereol.* 2014;72:259-62.
5. Liu LL, Lin LR, Tong ML, Zhang HL, Huang SJ, Chen YY, et al. Incidence and risk factors for the prozone phenomenon in serologic testing for syphilis in a large cohort. *Clin Infect Dis.* 2014;59:384-9. doi: 10.1093/cid/ciu325.
6. Smith G, Holman RP. The prozone phenomenon with syphilis and HIV-1 co-infection. *South Med J.* 2004;97:379-82. doi: 10.1097/01.SMJ.0000121204.58881.60.

Caso Clínico

7. Oanta A, Irimie M. Syphilitic balanitis of Follmann. *Int J Dermatol*. 2014;53:830-1. doi: 10.1111/ijd.12068.
8. Mainetti C, Scolari F, Lautenschlager S. The clinical spectrum of syphilitic balanitis of Follmann: report of five cases and a review of the literature. *J Eur Acad Dermatol Venereol*. 2016;30:1810-3. doi: 10.1111/jdv.13802.
9. Gayet-Ageron A, Lautenschlager S, Ninet B, Perneger TV, Combescure C. Sensitivity, specificity and likelihood ratios of PCR in the diagnosis of syphilis: a systematic review and meta-analysis. *Sex Transm Infect*. 2013;89:251-6. doi: 10.1136/sextrans-2012-050622.
10. Post JJ, Khor C, Furner V, Smith DE, Whybin LR, Robertson PW. Case report and evaluation of the frequency of the prozone phenomenon in syphilis serology - an infrequent but important laboratory phenomenon. *Sex Health*. 2012;9:488-90. doi: 10.1071/SH11156