


Qual o Papel da Carboxiterapia no Tratamento de Cicatrizes de Acne?

Joana Peixoto¹, Joana Resse Lascasas², Sofia Vedor³ 

¹Internship Family Medicine USF Mais Saúde, Unidade Local de Saúde do Alto Minho; Postgraduation in Aesthetical Medicine, Centro Internacional de Estudios de Córdoba, Universidad a Distancia de Madrid (UDIMA), Cordoba, Spain

²Internship Family Medicine UCSP Caminha, Unidade Local de Saúde do Alto Minho; Postgraduation in Aesthetical Medicine, Centro Internacional de Estudios de Córdoba, Universidad a Distancia de Madrid (UDIMA), Cordoba, Spain

³Postgraduation in Aesthetical Medicine, Centro Internacional de Estudios de Córdoba, Universidad a Distancia de Madrid (UDIMA), Cordoba, Spain

RESUMO – Introdução: A acne é uma condição extremamente prevalente. A reparação de lesões ativas de acne pode resultar no desenvolvimento de cicatrizes. As cicatrizes atróficas são as principais cicatrizes causadas pela acne e resultam da degradação das fibras de colágeno. A carboxiterapia é um método minimamente invasivo que consiste na injeção subcutânea de dióxido de carbono através de pequenas infiltrações na pele. O ambiente hipercápnico gerado resulta no aumento da deposição e reorganização das fibras de colágeno, facilitando a cicatrização e melhorando o aspeto da pele. O objetivo deste estudo é rever a evidência relativa ao papel da carboxiterapia no tratamento de cicatrizes faciais atróficas, isoladamente ou em combinação com outras técnicas. **Métodos:** Foi realizada uma pesquisa bibliográfica em várias bases de dados usando os termos MeSH “dióxido de carbono/terapia” e “feridas e lesões” para normas de orientação, revisões sistemáticas, ensaios clínicos randomizados e estudos observacionais, publicados nos últimos 20 anos em português, inglês ou espanhol. **Resultados:** Foram identificados 129 artigos, dos quais quatro estudos experimentais e uma série de casos foram selecionados. Comparando as técnicas de *microneedling* e carboxiterapia, ambas foram consideradas modalidades de tratamento não invasivo, com igual eficácia, tolerabilidade e segurança, resultando em alterações histopatológicas semelhantes. Por outro lado, apesar da melhoria das cicatrizes de acne em ambas as modalidades de tratamento, os resultados foram significativamente melhores a favor do laser fracionado de dióxido de carbono, apesar de estarem associados a um perfil de efeitos adversos mais desfavorável em relação à carboxiterapia. Quando essas técnicas são combinadas e a carboxiterapia é usada como método de subcisão, há uma melhoria mais acentuada e rápida na aparência das cicatrizes de acne. **Discussão:** A carboxiterapia é uma modalidade promissora no tratamento de cicatrizes atróficas da acne, isoladamente ou em combinação com outras técnicas.

PALAVRAS-CHAVE – Acne Vulgar/tratamento; Cicatriz/tratamento; Dióxido de Carbono/uso terapêutico.

What Role for Carboxytherapy in the Treatment of Acne Scars?

ABSTRACT – Introduction: Acne is an extremely prevalent condition. The healing of active acne lesions may result in the development of scars. Atrophic scars are the main scars caused by acne and result from the degradation of collagen fibers. Carboxytherapy is a minimally invasive method that involves the application of carbon dioxide subcutaneously through small infiltrations in the skin, which improves scar tissue by increasing collagen's deposition and reorganization. The aim of this study is to review the role of carboxytherapy in the treatment of atrophic facial scars, alone or in combination with other techniques. **Methods:** A literature search was conducted on several databases using MeSH terms “carboxytherapy”, “carbon dioxide/therapy” and “wounds” for guidelines, systematic reviews, randomized controlled trials, and observational studies, published over the last 20 years in Portuguese, English or Spanish languages. **Results:** A total of 129 articles were retrieved, of which four experimental studies and one case series were selected. Comparing the techniques of *microneedling* and carboxytherapy, both were considered non-invasive treatment modalities.

Correspondência: Joana Peixoto

Rua da Travessa, 1008

4905-650 Vila de Punhe

Viana do Castelo, Portugal

Tel.: +351 962423883

E-mail: joana.speixoto@gmail.com

DOI: <https://dx.doi.org/10.29021/spdv.78.4.1234>

Recebido/Received

2020/06/18

Aceite/Accepted

2020/08/30

Publicado/Published

2020/12/29

© Autor (es) (ou seu (s) empregador (es)) 2020 Revista SPDV. Reutilização permitida de acordo com CC BY-NC. Nenhuma reutilização comercial.

© Author(s) (or their employer(s)) 2020 SPDV Journal. Re-use permitted under CC BY-NC. No commercial re-use.

Artigo de Revisão

ties with equal effectiveness, tolerability and safety, resulting in similar histopathological changes. On the other hand, despite the improvement of acne scars in both treatment modalities, the results were significantly better in favor of carbon dioxide fractional laser, despite having more side effects than carboxytherapy. When these techniques are combined and carboxytherapy is used as a subcision method, there is a more marked and rapid improvement in the appearance of acne scars. **Discussion:** Carboxytherapy is a promising modality in the treatment of atrophic acne scars, alone or in combination with other techniques.

KEYWORDS – Acne Vulgaris/therapy; Carbon Dioxide/therapeutic use; Cicatrix/therapy.

INTRODUCTION

Acne is an extremely prevalent condition that affects almost everyone at some stage of their life. Although the severity and duration of this condition vary widely, scarring is more likely to occur in people with severe acne.¹ The healing of active acne lesions result in skin damage and development of scars. The main scars caused by acne, making up 80% to 90% of the total, are atrophic scars; these result from the degradation of collagen fibres and include 3 subtypes: ice-pick, boxcar and rolling scars.^{2,3} The treatment of these lesions has been carried out through general skin resurfacing, using deep chemical peelings or dermabrasion. More recently, the armamentarium increased with the use of lasers as a new resurfacing technique.

Carbon dioxide therapy consists in the administration of this substance for therapeutic purposes. This is not a novel technique - it has been used since the 17th century to treat chronic skin ulcers, but interest has resurged during the 1930s, being used to treat peripheral artery disease.⁴ The term 'carboxytherapy' was made popular in 1995, in a presentation by Luigi Parassoni at the XVI National Meeting of Aesthetic Medicine in Rome.⁵ Carbon dioxide is a colourless and odourless gas that, when injected transcutaneously, diffuses into the subcutaneous microcirculation. There the hypercapnia induces an increase in capillary blood flow that promotes a partial increase in oxygen tension and a right displacement of the oxygen dissociation curve (Bohr effect). Carbon dioxide administration improves local tissue blood flow velocity, increases the presence of local endothelial growth factors, stimulates angiogenesis and fibroblast collagen synthesis and, consequently, improves healing. At the bottom, carboxytherapy acts as a rehabilitator of the microcirculation.⁶ Carboxytherapy has some minor side effects, such as pain, ecchymosis and local cramps or burning sensation; nevertheless, major side effects are uncommon. During this therapy, small amounts of carbon dioxide are administered - about 30-50 mL / min, below the 12-20L of CO₂ administered to expand the abdominal cavity during laparoscopy - which are easily excreted by mild hyperventilation at the end of the procedure without risk of hypercapnia or respiratory acidosis.⁷

Nowadays, carboxytherapy is widely used in aesthetical and anti-ageing medicine, although it has been relatively under-researched. Traditionally, it presents good results in the treatment of vasculopathies, ischemic diseases, chronic venous insufficiency and lymphedema.^{6,8} In dermatology, this method is used in wound healing and in the treatment of capillary disorders, including alopecia and psoriasis.⁹ Carboxytherapy also has a useful role in aesthetic medicine, and its

use is indicated in skin rejuvenation and in the treatment of stretch marks, certain types of scars, fibrolipodystrophy and adhesions after liposuction.^{8,9}

The aim of this review is to determine the general effectiveness of carboxytherapy in the treatment of atrophic facial scars, alone or in combination with other techniques, through a systematic review of the literature.

METHODS

A literature search was conducted in April 2020 on several databases using the MeSH terms "carbon dioxide/therapeutic use" and "wounds and injuries". Searched databases included PubMed, Google Scholar, Web of Science, Scopus, Cochrane Library and SciELO.

Retrieved publication types included systematic reviews (SR) and meta-analyses (MA), randomized controlled trials (RCT), and observational studies, published over the last 20 years in Portuguese, English or Spanish languages. Articles were selected if meeting the following criteria: a) population: patients with atrophic acne scars; b) intervention: carboxytherapy, alone or in combination with other therapies; c) comparison: other techniques or no treatment; and d) outcome: primary outcomes of scar improvement.

Studies were excluded if not meeting inclusion criteria, diverging from the study purpose, representing duplicates, or having been included in a MA or SR.

RESULTS

Article selection flow is depicted on Fig. 1. Search strategy retrieved 129 articles, five of which met pre-defined inclusion criteria and were included. Four of them consisted in experimental studies and the other in a case series. Table 1 describes the characteristics and results of the experimental studies.

Effectiveness of carboxytherapy in acne scars' treatment

Moftah *et al* conducted an experimental study in which, by analysing clinical, histopathological and histometric variables, evaluated the effectiveness of carboxytherapy compared to microneedling in the treatment of acne scars.¹⁰ This study included 32 patients (10 male, 22 female) with age ranging between 18 and 40 years old. Six sessions were performed every 2 weeks consisting of microneedling on the right side and carboxytherapy on the left side of the face. Patients with other dermatological disorders and chronic medical conditions or who used topical formulations in the previous month, systemic medications and laser or light therapy

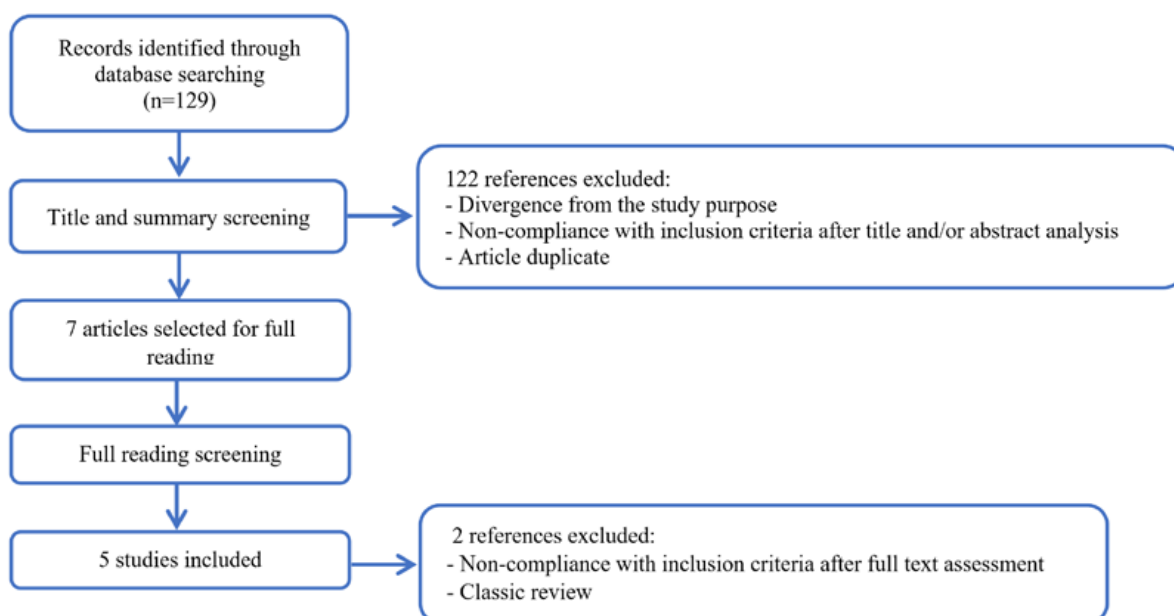


Figure 1 - Study selection flow during the review process.

in the previous 6 months were excluded. After either microneedling or carboxytherapy, there was a significant decrease of total acne scars and its 3 types separately ($p < 0.001$) and the grading of the severity after treatment achieved good or excellent response in most patients with both treatment modalities (only 6.25% of bad response with microneedling and 12.5% with carboxytherapy), with no significant difference between the 2 sides of face ($p = 0.07$) in which concerns scar count or the percentage of reduction of total scars and its types ($p > 0.05$). Reported side effects were mild and transient with both modalities and after 2 months after the last treatment there were no side effects detected. Histologically, at baseline, collagen fibres were disorganized with increased interfibrillary spaces and abnormal dense elastic tissue was in close contact with epidermis. Comparing with baseline, after treatment there was a significant improvement of character and organization of collagen and elastic fibres and a significant increase in epidermal thickness on both sides of the face, with no significant discrepancy between them ($p > 0.05$) (check Table 1 for further detail). Finally, when compared with baseline, the epidermal thickness was significantly increased either after microneedling ($p < 0.001$) or after carboxytherapy ($p = 0.002$), although there were no significant differences when comparing both sides of the face ($p = 0.2$).

Al Taweel *et al* aimed to compare the efficacy, safety and complications of the intradermal injection of platelet-rich plasma (PRP) combined with carbon dioxide therapies in the treatment of atrophic acne scars.¹¹ Their experimental study was conducted between March 2015 and August 2016 and included 40 patients, aged between 18 and 47 years old, divided in two equal groups. Each group of 20 patients

underwent three sessions of fractional injection of CO₂ and PRP laser or carboxytherapy combined with PRP injection. Patients on contraceptive pill, anticoagulant or aspirin, with type V or VI phototypes, treated with laser or chemical peel in the previous month, or with hepatitis B or C, HIV or immunosuppression were excluded. Group A was subjected to three sessions with 1-month interval of fractional CO₂ laser, followed by injection with autologous PRP in the treated areas. Group B patients had three sessions of PRP and carbon dioxide gas (carboxytherapy; CXT) intradermal injection in the treated areas. A follow-up was carried out 1 week after each session for early complications and 3 months after the last session. In order to evaluate their satisfaction with the treatment, an improving score was given to two dermatologists and to patients (Table 1). Dermatologists evaluation of scars' grading showed a statistically significant improvement in group A in comparison to group B ($p = 0.039$). Regarding patients' overall satisfaction, no statistically significant differences were obtained between the two groups ($p = 0.75$). There was no significant difference in response to treatment regarding predominant scar appearance in both groups (A: $p = 0.074$; B: $p = 0.052$). Additionally, non-smokers responded better to treatment than smokers, with statically significant differences ($p = 0.031$). Regarding side effects, although they do not mention p values, the authors refute the existence of statistically significant differences between the two groups regarding pain and post-treatment hyperpigmentation; nevertheless, the occurrence of oedema was significantly higher in group A.

'Subcision', a procedure used to treat depressed scars in which a hypodermic needle with three bevels is inserted into the skin surface and its edges are manoeuvred under the

Artigo de Revisão

Table 1 - Characteristics and results of the experimental studies of carboxytherapy on acne scars.

Study (year) LE	Subjects n (m/f) Ages (range)	Type of intervention	Skin type	Measures used to evaluate improvement	Follow-up	Scar improvement	Side-effects
Moftah <i>et al.</i> (2018) 3B	32 (10/22) 18-40 y	6 sessions of ML or CXT, 2-wk interval right vs left facial side	II-IV	1) Goodman and Baron scar grading: no change = poor response; 1 grade = good response; ≥ 2 grades reduction = excellent response 2) Acne Scars count 3) Skin biopsy (16 patients) 4) Epidermal thickness (16 pts) (computer-based software) Baseline vs 2 months	2 M	1) ML vs CXT Scar grading ($p > 0.05$) excellent 56.25% vs 43.75%; good 37.5% vs 43.75%; poor 6.25% vs 12.5% 2) Acne scars count: ML and CXT ($p < 0.001$); ML similar to CXT ($p = 0.07$). 3) Skin biopsy: Collagen improvement: ML $p = 0.02$, CXT $p = 0.01$; Elastic fibre: ML $p = 0.01$, CXT $p = 0.03$. 4) Epidermal thickness increase: ML ($p < 0.01$); CXT ($p = 0.02$), ML similar to CXT ($p = 0.2$).	Erythema and edema ML - for 1-2 D CXT - 10 min to 1 h Transient mild tolerable pain for ML/CXT. None at 2M
Al Taweel <i>et al.</i> (2018) 3B	40 (6/34) 18-47 y	3 sessions Group A: PRP+ CO2FL Group B: PRP+ CXT	II-IV	1) Dermatologist evaluation (photos) : Minimum: 0%-25%; Moderate; 25%-50%; Good: 50%-75%; Very good: 75%-100% 2) Patient satisfaction	1 wk after session + 3 M	Dermatologist evaluation: group A significantly better than B ($p = 0.039$) Patient satisfaction: Group A similar to B	Group A vs B: Pain: 70% vs 40% Hyperpigmentation: 20% vs 5%; Edema: 90% vs 50%
Kareem <i>et al.</i> (2019) 3B	20 17-42 y	FL (left) vs CXT + FL (right) 3 sessions 4-wk interval; CXT done 2 wk prior to FL		1) Goodman and Baron scar grading 2) Dermatologist evaluation (photos) skin texture, scar number, size, depth: weak: <25%; mild: 25%-50%; moderate: 51%-75%; excellent: >75%. 3) Patient satisfaction		1) CXT+FL improvement from 50% to 15% ($p = 0.005$); FL only: no significant change ($p = 0.687$). 2) CXT+FL > FL ($p = 0.003$). 3) Satisfaction CXT+FL vs FL ($p > 0.05$). High: 20% vs 0% Moderate: 35% vs 20% Mild: 25% vs 35%; None: 20% vs 45%	
Lee <i>et al.</i> (2016) 3B	14 (9/5) 19-37 y	CXT subcision (3) + FL (2) 2 wk interval	III-V	1) Goodman and Baron scar grading: 2) Dermatologist evaluation (photos) Scar improvement - 4-point GAS: mild (<25%); moderate (25-50%); marked (50-75%); excellent (>75%). 3) Histopathology (10 pts).	2 months	1) Change of scar severity grade in 29% ($p = 0.047$) 2) GAS improvement: 7% excellent 57% marked 29% moderate 7% mild 3) Increased dermal collagen thickening Elastic fiber straightning	Mild post-inflammatory hyperpigmentation observed in 2 patients, resolved after 1 to 3 months

m/f: male/female; M: months, pts: points; wk: week; y: years; vs: versus; CXT: carboxytherapy; CO₂: carbon dioxide; FL: fractional laser; GAS: global assessment scale; LE: level of evidence; ML: microneedling; PRP: platelet-rich plasma

defect to make subcutaneous cuts or splits. The goal is to break the fibrotic threads, which fix the scar to the underlying subcutaneous tissue. Depression is elevated by the liberating action of the procedure, as well as by the connective tissue that is formed during normal wound healing.¹² Kareem et al developed a single blind, comparative split-face study evaluating the effectiveness of carboxytherapy as a subcision method, combined with fractional carbon dioxide laser resurfacing in the treatment of atrophic acne scars.¹³ Patients with active acne, pregnancy or breastfeeding were excluded. This study included 20 participants with age ranging from 17 to 42 years old. All subjects underwent three sessions with a four-week interval of resurfacing with fractionated carbon dioxide laser on both sides of the face; two weeks before the laser sessions, the right side of the face was subjected to subcision with carboxytherapy. The Goodman and Baron's grading score was used to classify scar severity. Standardized photographs were taken at baseline and before and after each session. These photographs were presented to two independent blinded dermatologists, who evaluate the improvement in the quality of skin texture, number, size and depth of the lesions, using a quartile grading scale: weak: <25%; mild: 25%-50%; moderate: 51%-75%; excellent: >75%. The grade of acne severity on the right side of the face where carbon dioxide therapy was added was moderate in 50% of patients at baseline, decreasing significantly to 15% after treatment ($p=0.005$); on the left side there was no significant change in the degree of severity ($p=0.687$). The degree of improvement evaluated by dermatologists showed statistically significant improvement in the right side of the face, comparing to the left side ($p=0.003$). Patient satisfaction was higher in the right side of the face, lacking statistical significance ($p>0.05$) (Table 1).

Lee *et al* also studied the application of carboxytherapy as a subcision method. This study consisted of three sessions of carbon dioxide subcision every 2 weeks and two sessions of fractional laser every 4 weeks. No comparisons were made. Patients previously submitted to facial surgery or scarring procedures, patients with active acne, pregnant women or women who were breastfeeding were excluded. Acne scars severity was classified according to Goodman and Baron score. Two blinded dermatologists assessed the scar improvement based on standardized photographs taken at baseline and two months after the final session, using a 4-point global assessment scale (GAS) as follows: 1: mild (<25%); 2: moderate (25%–50%); 3: marked (50%–75%); 4: excellent (>75%); the GAS scores were averaged. The authors treated 14 patients with scar severity with a GAS at baseline evaluated as G2, 6 (43%) as G3 and 2 (14%) as G4. A change of severity grade of the acne scars was observed in 29% of patients after the final treatment. For the GAS score, clinical improvements were found in all patients. Regarding side effects, mild post-inflammatory hyperpigmentation was observed in 2 patients, which disappeared after 1 to 3 months. Among the different subtypes of acne scars, the boxcars smaller than 3 mm showed the

most improvement, and superficial elastolysis showed the least improvement after the treatment, with statistical significance ($p=0.047$). Histological evaluation of the skin biopsy specimens taken before and after treatment in 10 patients showed increased dermal collagen with thickening of the dermis and straightening of elastic fibres in the reticular dermis after the treatment.

Finally, Koutná described her personal experience in the treatment of 280 patients with carboxytherapy,¹⁴ including acne scars. The author reported good response to carboxytherapy in superficial soft flat scars after excoriations (3 patients), lesions that also improve spontaneously just with medical acne therapy, but some patients demand for treatment when the scars are visible as red-purple or pigmented patches. In patients with 'saucer-shape' (8 patients) and 'ice pick' scars (8 patients) or large pores the author recognized at least some improvement. Nonetheless, these results were generally not so significant to recommend the general use of this technique. Although therapy by ablative lasers can reach better results, certain 'ice pick' scars and large pores improve with carboxytherapy in a way which is satisfactory to the patient. Curiously, it was shown that this improvement was usually reduced if the patient used make-up.

Quality and characteristics of studies

The experimental studies found included one trial of carboxytherapy alone and the other two in combination with platelet rich plasma or as a subcision method before carbon dioxide fractional laser. Only one of the studies made mention to blinding. Most of the studies were of poor quality and included 40 or less participants. The interventions were clearly described, but different in all studies. Only one study referred to pre-operative and postoperative treatments. The methods for measuring scar improvement varied between studies. In general, outcomes were measured by comparison of the severity of scars before and after treatment using a grading scoring system (Goodman and Baron), recurring to standardized photographs. This scale has not been validated and its reliability depends on the grader's level of training in dermatology and even among trained specialists, this subjective system does not reach an 'excellent' level of reproducibility.¹⁵ Lee *et al* evaluated clinical and histological variables, but they did not compare carboxytherapy combined with carbon dioxide laser with other treatment modalities.¹⁶ In the study conducted by Mofthah *et al*, the population and study design were well defined and it included clinical and histopathological variables.¹⁰ Even so, these two studies did not take into account patient satisfaction and psychological status. This is a disadvantage because results quantified by clinicians may not reflect patient perception. In the other studies, although they measured only clinical outcomes, patient evaluation and satisfaction were considered. No studies measured the psychological status of the patients either before or after treatment. In all studies evaluated, there was no report on the completion of the follow-up or the reasons for any loss in the follow-up.

Artigo de Revisão

DISCUSSION

Despite the scarcity of good quality information, in order to systematize the information available, it is important to register a systematic review to inform patients, clinicians and healthcare purchasers. Although there may be some benefits in administering carboxytherapy, most of the available studies have few participants and therefore the benefits have not been adequately quantified and, due to the inherent bias, they almost certainly overestimate the true effect of treatment. Furthermore, only one study evaluated the efficacy of carboxytherapy as a single treatment.

Acne is a common condition experienced by up to 80% of people between 11 and 30 years of age and by up to 5% of older adults.³ An epidemiological survey conducted in France with more than 3000 women with acne showed that total acne prevalence was 41% and nearly half of patients had scars and/or pigmented macules as acne sequelae.¹⁷ Atrophic scars are a dramatic consequence of acne, resultant from the severe inflammatory response to *Propionibacterium acnes*.³ There are multiples treatment options, including subcutaneous or dermal fillers, chemical peels, microdermabrasion or particulate resurfacing, primary elliptical excision, punch excision, punch elevation, punch autografting, dermal grafting, dermal planning, subcision, dermabrasion, and laser.³ Nevertheless, the best treatment or treatment combinations are still not known.

Comparing carboxytherapy and fractional carbon dioxide laser, improvement of acne scars was noticed in both treatment modalities, with higher and statistically significant results in favour of fractional carbon dioxide laser, but with a more unfavourable profile of side effects. On the other hand, subcision via carboxytherapy accelerates the improvement of atrophic acne scars when combined with the fractionated carbon dioxide laser resurfacing, making this combination a promising treatment option.

Similar histopathological changes were observed after carboxytherapy and microneedling, comprehending an increase in collagen and elastic fibres, with its reorganization. Both modalities are equally effective, tolerable, safe, and non-invasive treatment modalities of atrophic acne scars.

Although there is only scarce evidence in this regard, facial disfigurement caused by acne scars can have a significant social and psychological impact on the patient's life. In addition, evidence on the impact of treatment with carboxytherapy on psychological status or quality of life is also lacking. In fact, the need to treat these complications is often under-recognized and undervalued. Clarification to the patient is essential, and the patient should be informed about the absence of randomized clinical trials, and any results presented will be inflated by bias and subject to the perceptions of clinicians and patients. Although aesthetical treatments are not essential or lifesaving, and even though patients are free to acquire these treatments, information about effectiveness and safety of these procedures, should be available which in not the case.

Carboxytherapy is a relatively cheap and apparently safe procedure that may have a role in the treatment of atrophic acne scars. In order to make a positive advice, more studies are necessary to prove its clinical and psychological benefits and the effect on quality of life. At present, the lack of convincing evaluation by randomized clinical trials does not allow a general recommendation of this technique, despite the patient's recognition of the need for treatment.

CONCLUSION

Carboxytherapy is a minimally invasive technique, well tolerated by patients, economically acceptable and can be conducted in an outpatient setting. More studies are necessary in order to recommend it in the treatment of atrophic acne scars, alone or in combination with other techniques.

Conflitos de interesse: Os autores declaram a inexistência de conflitos de interesse na realização do presente trabalho.

Fontes de financiamento: Não existiram fontes externas de financiamento para a realização deste artigo.

Consentimento: Consentimento do doente para publicação obtido.

Proveniência e revisão por pares: Não comissionado; revisão externa por pares.

Conflicts of interest: The authors have no conflicts of interest to declare.

Financing support: This work has not received any contribution, grant or scholarship.

Patient Consent: Consent for publication was obtained.

Provenance and peer review: Not commissioned; externally peer reviewed

ORCID

Joana Peixoto

<https://orcid.org/0000-0002-7807-876X>

Joana Resse Lascasas

<https://orcid.org/0000-0003-3974-9636>

Sofia Vedor

<https://orcid.org/0000-0001-7421-5459>

REFERENCES

1. Layton AM, Henderson CA, Cunliffe WJ. A clinical evaluation of acne scarring and its incidence. *Clin Exp Dermatol.* 1994;19:303-8.
2. Jordan R, Cummins C, Burls A. Laser resurfacing of the skin for the improvement of facial acne scarring: a systematic review of the evidence. *Br J Dermatol.* 2000;142:413-23.
3. Jacob CI, Dover JS, Kaminer MS. Acne scarring: a classification system and review of treatment options. *J Am Acad Dermatol.* 2001;45:109-17.
4. Duchêne-Marullaz P. Pharmacologie, pharmacologie clinique et effets thérapeutiques du gaz thermal de Royat Sem Hop Ther. 1977;53:361-2.
5. Bartoletti CA PL, Varlaro V. La carbossiterapia: una

Artigo de Revisão

- metodic in evoluzione. Riv Med Estetica 1997;2.
6. Varlaro V, Manzo G, Mugnaini F, Bisacci C, Fiorucci P, De Rango P, et al. Carboxytherapy: effects on microcirculation and its use in the treatment of severe lymphedema. *Acta Phlebol.* 2007;8:79-91.
 7. Parassoni L AF, Varlaro V, Curri SB. La carbossiterapia in tema di meccanismi d'azione. *Riv Med Estetica.* 1997; 21.
 8. Zenker S. Carboxytherapy: Carbon Dioxide injections in *AesthetiC Medicine.* Prime-journal.com. 2012:42-50.
 9. Koutna N. Carboxytherapy – new, non-invasive method of aesthetic medicine. *Cas Lek Cesk.* 2006;145:841-3.
 10. Mofteh NH, El Khayyat MAM, Ragai MH, Alaa H. Carboxytherapy versus skin microneedling in treatment of atrophic postacne scars: a comparative clinical, histopathological, and histometrical study. *Dermatol Surg.* 2018;44:1332-41. doi: 10.1097/DSS.0000000000001560.
 11. Al Taweel AI, Al Refae AA, Hamed AM, Kamal AM. Comparative study of the efficacy of Platelet-rich plasma combined with carboxytherapy vs its use with fractional carbon dioxide laser in atrophic acne scars. *J Cosmet Dermatol.* 2019;18:150-5. doi: 10.1111/jocd.12561.
 12. Orentreich DS, Orentreich N. Subcutaneous incisionless (subcision) surgery for the correction of depressed scars and wrinkles. *Dermatol Surg.* 1995;21:543-9.
 13. Abdel Kareem IM, Fouad MA, Ibrahim MK. Effectiveness of subcision using carboxytherapy plus fractional carbon dioxide laser resurfacing in the treatment of atrophic acne scars: comparative split face study. *J Dermatolog Treat.* 2020;31:296-9. doi: 10.1080/09546634.2019.1595505.
 14. Koutna N. Carboxytherapy in Aesthetic Dermatology – Experiences after the Treatment of 280 Patients. In: Prendergast P, Stiffman M, editors. *Aesthetic Medicine.* Berlin: Springer; 2012. p. 547-76. doi: 10.1007/978-3-642-20113-4_43.
 15. Petukhova TA, Foolad N, Prakash N, Shi VY, Sharon VR, O'Brecht L, et al. Objective volumetric grading of postacne scarring. *J Am Acad Dermatol.* 2016;75:229-31. doi: 10.1016/j.jaad.2016.03.002.
 16. Lee SJ, Suh DH, Chang KY, Kim HJ, Kim TI, Jeong KH, et al. The efficacy and safety of subcision using CO2 gas combined with fractional laser for acne scars: Clinical and microscopic evaluation. *J Cosmet Laser Ther.* 2016;18:417-20. doi: 10.1080/14764172.2016.1202418.
 17. Poli F, Dreno B, Verschoore M. An epidemiological study of acne in female adults: results of a survey conducted in France. *J Eur Acad Dermatol Venereol.* 2001;15:541-5.