

CASE REPORT

Steroid-resistant Acute Generalized Exanthematous Pustulosis Mimicking Generalized Pustular Psoriasis Successfully Treated by Methotrexate

Pustulose Exantemática Generalizada Aguda Resistente a Esteroides que Mimetiza Psoríase Pustulosa Generalizada Tratada com Sucesso por Metotrexato

Received/Recebido
2020/12/26Accepted/Aceite
2021/02/07Published/Publicado
2021/09/30Khairuddin Djawad^{1*} ¹Department of Dermatology and Venereology, Faculty of Medicine, Hasanuddin University, Makassar, South Sulawesi, Indonesia.

ABSTRACT – Acute generalized exanthematous pustulosis is a rare drug-induced eruption that is characterized by sterile non-follicular pustules arising on an often edematous diffuse erythematous background. Generalized pustular psoriasis is an acute and severe clinical form of psoriasis presenting as pustular eruption with erythematous base. Differentiating both diseases is often challenging because of their clinical and histopathological similarities.

A 62-year-old woman presented with pustular eruption and fever three days after taking propyphenazone. Laboratory findings revealed leukocytosis and neutrophilia. Histopathological findings revealed a subcorneal spongiform pustule filled with neutrophils and perivascular inflammatory cell infiltration with neutrophils in the dermis. She was initially treated with systemic steroids, however, the lesions showed insignificant improvement. Treatment was then shifted to methotrexate which resulted in a dramatic clinical improvement.

KEYWORDS – Acute Generalized Exanthematous Pustulosis; Methotrexate.

RESUMO – A pustulose exantemática aguda generalizada é uma reação adversa a fármacos rara caracterizada por pústulas estéreis não foliculares que surgem frequentemente em pele eritematosa. A psoríase pustulose generalizada é uma forma aguda e grave de psoríase que se manifesta por erupção pustulosa em base eritematosa e que pode ser difícil de distinguir da pustulose exantemática aguda generalizada tanto do ponto de vista clínico como histopatológico.

Apresentamos o caso de mulher de 62 anos com erupção pustular e febre três dias depois de tomar propifenazona, com leucocitose e neutrofilia. O estudo histopatológico mostrou uma pústula espongiiforme subcórnea com neutrófilos e um filtrado inflamatório dérmico perivascular com neutrófilos e alguns eosinófilos. Dada a fraca resposta aos corticoides foi tratada com metotrexato com boa resposta.

PALAVRAS-CHAVE – Metotrexato; Pustulose Exantematosa Aguda Generalizada.

INTRODUCTION

Acute generalized exanthematous pustulosis (AGEP) is a rare type of pustular cutaneous drug reaction. It is mostly drug induced with an incidence of around 1-5 per million population per year.^{1,2} All ages can be affected, and women are more prone to this reaction. Clinically, AGEP is characterized by high fever and the appearance of numerous small sterile non-follicular pustules on an often edematous and diffuse erythematous base which begins on the face or major intertriginous zones.^{2,3} AGEP should be differentiated from other skin diseases with pustular eruption, such as impetigo, pemphigus foliaceus, staphylococcal scalded skin syndrome, subcorneal pustular dermatosis, and generalized pustular psoriasis (GPP).⁴ AGEP and GPP are difficult to distinguish due to the similar clinical presentation and initial clinical symptoms. Histopathological examination in AGEP instead of GPP involves the presence of eosinophils in pustules or dermis, necrotic keratinocytes, dermal infiltrates with numerous neutrophils and dilated but not tortuous blood vessels, whereas GPP also shows psoriasiform

epidermis.⁵ Even though differentiation of AGEP from GPP may be difficult, histopathological analysis and some clinical features may be helpful.⁴ We report a case of AGEP which, due to steroid-resistance, was confused with GPP and eventually was successfully treated with methotrexate.

CASE REPORT

A 62-year-old woman visited the emergency department with generalized erythematous pustular eruption, generalized edema, and high fever for approximately five days. The patient had a history of taking propyphenazone one week before admission. Pustular lesions began appearing on the trunk on the second day after drug use and by the day of admission to our unit, had spread to all body regions. Neither the patient nor her family had a history of psoriasis. The patient was obese (body weight 90 kg, height 160 cm, BMI 35 kg/m²) and was using no other medication.

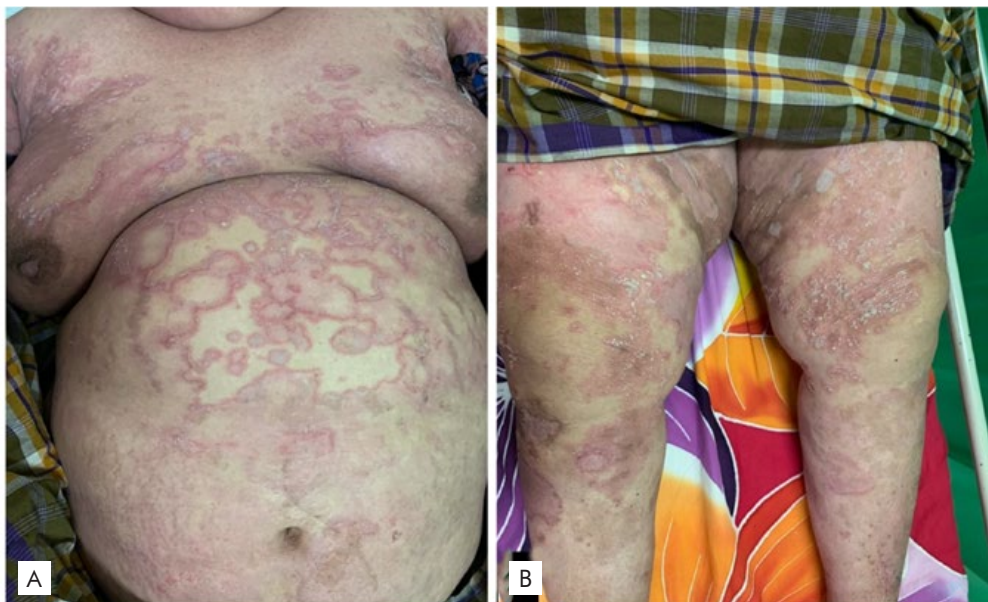


Figure 1 - Erythematous scaly patches with multiple tiny pustules observed on the entire body.

Clinical examination revealed high body temperature (38.50C) and generalized non-follicular pustules with scaly erythematous base on her entire body (Fig. 1), but mostly on the trunk and large axillary, inguinal and sub-mammary body folds. The face was spared. Laboratory tests revealed leukocytosis (18.9x103/uL) with neutrophilia (81%) and elevated erythrocyte sedimentation rate (40 mm/hour). Liver and kidney function tests were normal. Histopathological examination revealed subcorneal spongiform pustule with neutrophils in the epidermis and perivascular inflammatory cell infiltration with neutrophils and some eosinophils in the dermis (Fig. 2). The diagnosis of AGEP triggered by the NSAID propyphenazone was established and treatment started with intravenous methylprednisolone 125 mg twice daily, topical desoxymethasone, and topical emollients. Fever and skin lesions improved, but new pustular lesions kept occurring as soon as the steroid dose was reduced. After six days, the patient was given methotrexate (7.5 mg/week) and the steroid dose was slowly tapered. Pustular lesions and erythematous scaly patches improved within six weeks (Fig. 3). After 10 weeks of MTX administration lesions completely resolved,

leaving only hyperpigmented macules. No recurrence occurred during the next six months of follow-up.

DISCUSSION

AGEP is a pustular eruption with acute onset that is rare, severe, and has a typical clinical picture.⁶ Mucocutaneous features consist of tens to hundreds of small, sterile, non-follicular pustules within an erythematous basis with or without minimal mucous membrane involvement and are usually pruritic. Distribution includes trunk and intertriginous areas, as in our patient. Leukocytosis with high neutrophil counts and fever is also a characteristic sign of AGEP.⁷

AGEP is a sterile neutrophilic inflammatory response associated with activated T-cells in a so-called type IVd hypersensitivity.⁸ After exposure to the causative agent, activated specific CD4 and CD8 T cells migrate into the dermis and epidermis. Drug-specific CD8 T cells use the mechanism of perforin/granzyme B and Fas ligand to induce apoptosis of keratinocytes, which causes tissue damage. In the early

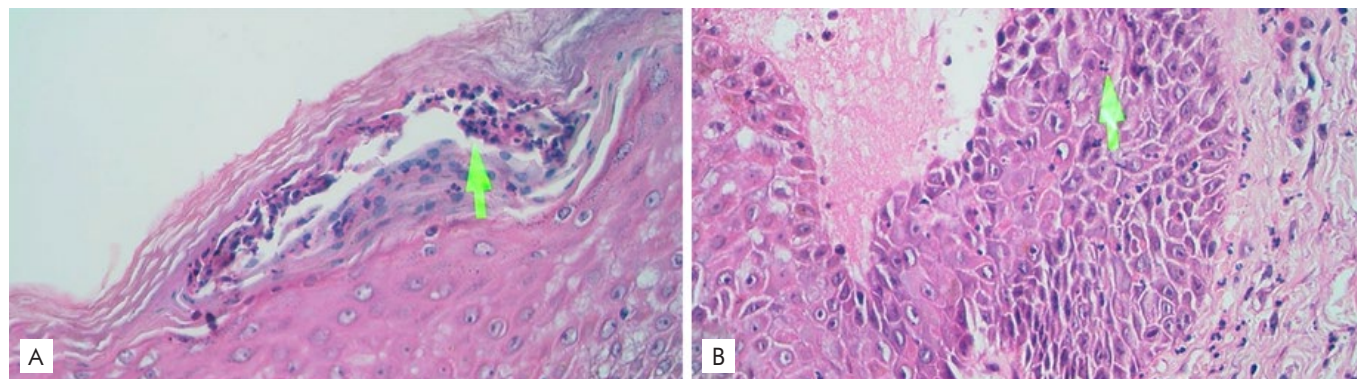


Figure 2 - Histopathological examination revealed subcorneal spongiform pustule (A) and perivascular inflammatory cell infiltration in the dermis (B). (H&E, x40).

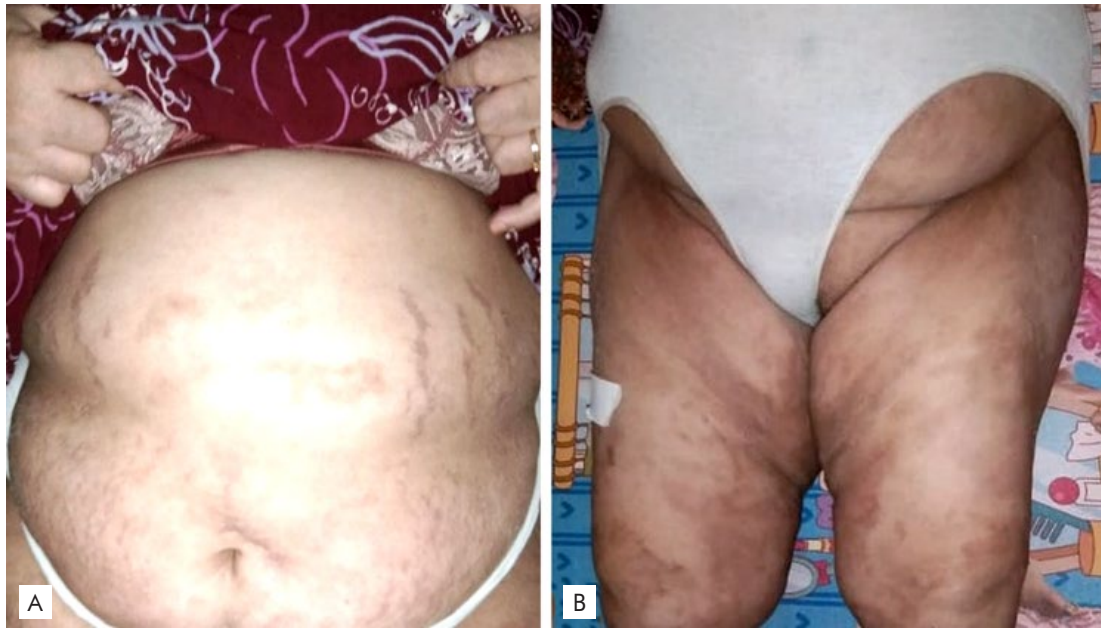

Figure 3 - Generalized hyperpigmented macules after resolution.

stages of AGEP, vesicles are rich in drug-specific CD4 T cells which release a number of powerful neutrophilic cytokines and lead to neutrophil chemotaxis into vesicles and cause transformation of vesicles into sterile pustules.⁹ Drug-specific T cells in AGEP patients produce chemokines, namely CXCL8/IL-8, which is significantly involved in the chemotaxis of neutrophils and pustule formation. High levels of IL-17, IL-22, and granulocyte-macrophage colony-stimulating factor (GM-CSF) also play a significant role in neutrophilic activity in AGEP.¹⁰

AGEP must be distinguished from various skin diseases that have a pustular eruption, such as impetigo, pemphigus foliaceus, staphylococcal blistering skin syndrome, veiled pustular skin syndrome, and especially generalized pustular psoriasis (GPP). Although differentiating AGEP from GPP is quite difficult, it may be distinguished by histopathological analysis and some clinical features.⁴ Generalized pustular psoriasis (GPP) is one of the typical types of psoriasis with an average incidence of age of the 4th decade, but there a number of reports in children and adolescents. Typical features include fever and other systemic symptoms such as malaise, arthralgia, anorexia, and diarrhea which are then followed by sterile acute eruption, sub-corneal pustules with an erythematous skin base with 2-3 mm diameter. Nevertheless AGEP and GPP can co-exist and GPP can even predispose to AGEP, as both diseases may be associated with a mutation in IL36R, favoring neutrophilic inflammation.^{11,12}

AGEP is associated with drugs as a cause in more than 90% of cases, most commonly associated with antibiotics, antifungals, diltiazem and antimalarials and less frequently by dapsone, antiepileptic, NSAID, and even corticosteroids.¹³ Paramex® (propyphenazone), a non-acidic pyrazole NSAID with potent analgesic activity and minimal anti-inflammatory activity,¹⁴ has not apparently been described as a cause of AGEP.

AGEP usually has a good prognosis and most cases do not require management other than stopping the causative drug and supportive care,¹⁵ but some few cases (<5%) can be life-threatening. Our case did not show rapid remission despite systemic steroid treatment and methotrexate (7.5 mg/week) was used with resolution within six

weeks. The mechanism of action of methotrexate correlates with the pathophysiology of AGEP which is a neutrophilic inflammatory response associated with T cells. Methotrexate is generally known as an antimetabolite that inhibits dihydrofolate reductase, an enzyme responsible for the conversion of folic acid to tetrahydrofolic acid in active cell division. It is an anti-inflammatory and immunosuppressive agent by inhibiting lymphocytes and there is another effect, the reduction of neutrophil release.¹⁶ Feketeova et al showed a successful treatment of rheumatoid arthritis by MTX which was likely caused by early and considerable inhibition of neutrophil chemotaxis.¹⁷

To our knowledge, no cases of AGEP treated with methotrexate have been previously reported. Two previously reported cases of steroid-resistant AGEP showed clinical improvement after the administration of dapsone with a dose of 50 mg/day⁴ and cyclosporine 4 mg/kgBW/day¹⁸, respectively. Thus, our report shows that MTX can also be considered as a treatment option in steroid-resistant AGEP.

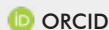
CONCLUSION

This case presents a generalized pustular eruption initially diagnosed as AGEP which, due to the unexpected clinical journey, later became difficult to distinguish from GPP. However, generalized pustular eruption accompanied by sudden fever, leukocytosis with neutrophilia, a history of new medication, subcorneal spongiform pustule with neutrophils in the epidermis and perivascular inflammatory cell infiltration with neutrophils and some eosinophils in the dermis, and no history of psoriasis favored the diagnosis as AGEP. As the skin lesion worsened after corticosteroid dose reduction, the patient was given methotrexate (7.5 mg/week) and showed significant reduction in pustular lesions and scales within six weeks.

Conflicts of Interest: The authors have no conflicts of interest to declare. Financing Support: This work has not received any contribution, grant or scholarship.

Confidentiality of Data: The authors declare that they have followed the protocols of their work center on the publication of data from patients. **Patient Consent:** Consent for publication was obtained. **Provenance and Peer Review:** Not commissioned; externally peer reviewed.

Conflitos de Interesse: Os autores declaram a inexistência de conflitos de interesse na realização do presente trabalho. **Fontes de Financiamento:** Não existiram fontes externas de financiamento para a realização deste artigo. **Confidencialidade dos Dados:** Os autores declaram ter seguido os protocolos da sua instituição acerca da publicação dos dados de doentes. **Consentimento:** Consentimento do doente para publicação obtido. **Proveniência e Revisão por Pares:** Não comissionado; revisão externa por pares.



ORCID

Khairuddin Djawad: <https://orcid.org/0000-0002-4569-6385>

Corresponding Author: Khairuddin Djawad

Address: Jl. Perintis Kemerdekaan Km 11, Makassar, South Sulawesi, Indonesia, 90245

E-mail: duddin@gmail.com

© Author(s) (or their employer(s)) 2021 SPDV Journal. Re-use permitted under CC BY-NC. No commercial re-use.

© Autor (es) (ou seu (s) empregador (es)) 2021 Revista SPDV. Reutilização permitida de acordo com CC BY-NC. Nenhuma reutilização comercial.

REFERENCES

1. Shalom G, Davidovici BB, Horev A, Halevy S. Acute generalized exanthematous pustulosis and psoriasis: what can be learned from comorbidities. *G Ital di Dermatologia e Venereol.* 2019;154:413-7. doi: 10.23736/S0392-0488.19.06157-1.
2. Valeyrie-Allanore L, Obeid G, Revuz J. Drug Reactions. In: Bologna JL, Schaffer JV, Cerroni L, editors. *Dermatology.* 4th ed. Philadelphia: Elsevier; 2017. p. 348.
3. Sidoroff A. Acute generalized exanthematous pustulosis. *Chem Immunol Allergy.* 2012;97:139-48. doi: 10.1159/000335625.
4. Duman H, Topal IO, Kocaturk E, Cure K, Mansuraglu I. Acute generalized exanthematous pustulosis induced by hydroxychloroquine: a case with atypical clinical presentation. *An Bras Dermatol.* 2017;92:404-6. doi: 10.1590/abd1806-4841.20175561.
5. Kardaun SH, Kuiper H, Fidler V, Jonkman MF. The histopathological spectrum of acute generalized exanthematous pustulosis (AGEP) and its differentiation from generalized pustular psoriasis. *J Cutan Pathol.* 2010;37:1220-9.
6. Halevy S, Kardaun SH, Davidovici B, Wechsler J. The spectrum of histopathological features in acute generalized exanthematous pustulosis: a study of 102 cases. *Br J Dermatol.* 2010;163:1245-52.
7. Hotz C, Valeyrie-Allanore L, Haddad C, Bouvresse S, Ortonne N, Duong TA, et al. Systemic involvement of acute generalized exanthematous pustulosis: a retrospective study on 58 patients. *Br J Dermatol.* 2013;169:1223-32. doi: 10.1111/bjd.12502.
8. Feldmeyer L, Heidemeyer K, Yawalkar N. Acute Generalized Exanthematous Pustulosis: Pathogenesis, Genetic Background, Clinical Variants and Therapy. *Int J Mol Sci.* 2016;17:1214.
9. Szatkowski J, Schwartz RA, Edin F. Acute generalized exanthematous pustulosis (AGEP): A review and update. *J Am Acad Dermatol.* 2015;73:843-8. doi: 10.1016/j.jaad.2015.07.017.
10. Kabashima R, Sugita K, Sawada Y, Hino R, Nakamura M, Tokura Y. Increased circulating Th17 frequencies and serum IL-22 levels in patients with acute generalized exanthematous pustulosis. *J Eur Acad Dermatol Venereol.* 2011;25:485-8. doi: 10.1111/j.1468-3083.2010.03771.x.
11. Benjegerdes KE, Hyde K, Kivelevitch D, Mansouri B. Pustular psoriasis: pathophysiology and current treatment perspectives. *Psoriasis.* 2016;6:131-44. doi: 10.2147/PTT.S98954.
12. Gudjonsson JE, Elder JT. Psoriasis. In: Kang S, Amagai M, Bruckner AL, Enk AH, Margolis DJ, McMichael AJ, et al, editors. *Fitzpatrick's Dermatology.* 9th ed. New York: Mc Graw Hill; 2019. p. 457-97.
13. De A, Das S, Sarda A, Pal D, Biswas P. Acute generalised exanthematous pustulosis: An update. *Indian J Dermatol.* 2018;63:22-9. doi: 10.4103/ijid.IJD_581_17.
14. Radwan M, Dalby K, Kaoud T. Propyphenazone-based analogues as prodrugs and selective cyclooxygenase-2 inhibitors. *ACS Med Chem Lett.* 2014;5:983-8. Kaoud T. Propyphenazone-based analogues as prodrugs and selective cyclooxygenase-2 inhibitors.
15. Marina S, Semkova K, Guleva D, Kazandjieva J. Acute generalized exanthematous pustulosis (AGEP): a literature review. *Scripta Sci Med.* 2013;4:7-12.
16. Perez A, Woods A, Grattan C. Methotrexate: a useful steroid-sparing agent in recalcitrant chronic urticaria. *Br J Dermatol.* 2009;162:191-4.
17. Feketeová L, Janbová P, Moravcová P, Janegová A, Bauerová K, Ponint S, et al. Effect of methotrexate on inflammatory cells redistribution in experimental adjuvant arthritis. *Rheumatol Int.* 2012;32:3517-23. doi: 10.1007/s00296-011-2177-3.
18. Yalçın B, Çakmak S, Yıldırım B. Successful treatment of hydroxychloroquine-induced recalcitrant acute generalized exanthematous pustulosis with cyclosporine: case report and literature review. *Ann Dermatol.* 2015;27:431-4. doi: 10.5021/ad.2015.27.4.431.