

## CASE REPORT

# Carcinoma Basocelular com Metastização Óssea Disseminada: Um Desfecho Involgar da Doença Maligna Mais Comum

## Basal Cell Carcinoma with Disseminated Bone Metastization: An Unusual Outcome of the Most Common Malignancy

Received/Recebido  
2021/01/12Accepted/Aceite  
2021/03/22Published/Publicado  
2021/09/30Luísa Rolim<sup>1</sup>, Bruno M Fernandes<sup>1</sup>, Carolina Carvalho<sup>1</sup>, António Silva<sup>1</sup>, Joana Calvão<sup>2</sup> , Ricardo Vieira<sup>2</sup> , Margarida Borrego<sup>1</sup><sup>1</sup>Department of Radiation Oncology, Coimbra University Hospital, Coimbra, Portugal<sup>2</sup>Department of Dermatology, Coimbra University Hospital, Coimbra, Portugal

**ABSTRACT** – Basal cell carcinoma is the most common skin cancer, with a very low incidence of metastases, associated with high morbidity and mortality. The morpheiform clinical variant is uncommon, presenting an aggressive growth pattern. Early diagnosis and new targeted therapies for metastatic disease are important to improve survival rates.

We present the case of a 29-year-old patient with morpheiform basal cell carcinoma in the right genian region. Due to local recurrences, he underwent surgery and adjuvant radiotherapy. For extensive metastatic bone involvement, the patient started vismodegib and, later, pembrolizumab, and also performed palliative radiotherapy. Despite several lines of systemic therapy, the disease progressed, and the patient died after 8 years of follow-up.

This case shows how crucial it is to identify risk factors for metastatic basal cell carcinoma and highlights the need to improve target therapies and tailor them to the patient's biological profile.

**KEYWORDS** – Carcinoma, Basal Cell/secondary; Carcinoma, Basal Cell/drug therapy; Neoplasm Metastasis/radiotherapy; Skin Neoplasms/drug therapy.

**RESUMO** – O carcinoma basocelular é o cancro de pele mais comum, com uma incidência muito baixa de metástases, associada a alta morbidade e mortalidade. A variante clínica morfeiforme é incomum, apresentando um padrão de crescimento agressivo. O diagnóstico precoce e as novas terapias-alvo para a doença metastática são importantes para melhorar as taxas de sobrevivência.

Apresentamos o caso de um doente de 29 anos, com carcinoma basocelular morfeiforme na região geniana direita. Devido a recorrências locais, foi submetido a cirurgia e a radioterapia adjuvante. Por extenso envolvimento ósseo metastático, o doente iniciou vismodegib e, mais tarde, pembrolizumab, tendo realizado radioterapia paliativa antiálgica. Apesar das várias linhas de terapêutica sistémica, a doença progrediu, e o doente faleceu após 8 anos de seguimento.

Este caso mostra como é crucial identificar fatores de risco para o basalioma metastático, e destaca a necessidade de melhorar as terapias-alvo e de adaptá-las ao perfil biológico do doente.

**PALAVRAS-CHAVE** – Carcinoma Basocelular/secundário; Carcinoma Basocelular/tratamento farmacológico; Metástase Neoplásica/radioterapia; Neoplasias da Pele/tratamento farmacológico.

## INTRODUCTION

Basal cell carcinoma (BCC) represents the most common human neoplasm in Caucasians, corresponding to about 80% of nonmelanoma skin tumors.<sup>1</sup>

It is a malignant epidermal tumor, locally invasive, slow-growing, and whose incidence of metastases is greatly reduced, ranging from 0.0001% to 0.55%.<sup>2</sup>

Most metastatic BCC's originate from the head and neck, with the bone being involved in approximately 20% to 30% of cases, since metastatic dissemination occurs more frequently to the regional lymph nodes (60%) and the lung (40%).<sup>3</sup>

Although, surgery represents the most successful treatment for the majority of BCC's, there is no effective therapy for locally advanced or

metastatic disease. The average survival is only 8 - 10 months.<sup>4,5</sup>

New molecular therapies, such as anti-epidermal growth factor receptor drugs and inhibitors of the Hedgehog (Hh) pathway, are emerging as more promising alternatives for patients with metastatic BCC.<sup>6</sup>

We present the case of a young adult with cutaneous BCC of the face with an atypically extensive bone metastases development, aiming to improve the management of this type of tumor and to highlight some of the latest trends in molecular therapy for advanced BCC.

## CLINICAL CASE

In November 2011, a 29-year-old male patient with prolonged smoking history (14 pack-years) and no relevant previous medical history, namely primary/acquired immunodeficiency, prior radiation

therapy, or knowledge about any genodermatosis with oncogenic predisposition (e.g., Gorlin syndrome), was diagnosed with morpheaform BCC, after excision of an exophytic lesion located in the right genian region. He showed no other lesions or palpable cervical masses.

Subsequently, he underwent two surgical excisions, with comprehensive intraoperative margin control, due to local recurrences: the first, in December 2012 and the other in May 2015, were both incomplete. The histopathological examination of the latter revealed a BCC lesion with 1.8 cm of extension and 3 to 4 mm of thickness, of infiltrative morphology, aggressive behavior, perineural invasion and deep (with muscle invasion) and internal margin involvement.

Surgical margins were enlarged (with excision of previous scar), which proved to be free of neoplastic tissue.

In June 2015, the patient had a reconstruction of the right hemiface with cervical-thoracic flap, with adequate scar evolution and satisfactory aesthetic result. Clinically, he had no pain, although he evidenced sensory hypoesthesia at the right hemiface level.

Between August and September 2015, the patient received adjuvant three-dimensional conformal radiotherapy (3D-CRT), with 50 Gy in 25 fractions, directed to the right hemiface, followed by a boost of 10 Gy in 5 fractions to the tumor bed (Fig. 1), without significant complications.

The patient remained under clinical surveillance, with no evidence of locoregional disease and recovery of facial sensitivity.

By the end of 2016, due to low back pain, the patient performed a computed tomography (CT) scan of the lumbosacral spine that showed bone changes in the body of S1 and in the right wing of

the sacrum. On May 2017, a biopsy of the sacral lesion revealed a morpheaform BCC bone metastasis.

The restaging 18F-fluorodeoxyglucose (18F-FDG) PET-CT showed extensive lytic bone metastases.

The patient started vismodegib (150 mg, once daily) in June 2017 and, in parallel, he was treated with 3D-CRT to a total dose of 16 Gy in 4 fractions directed to segments D7-D10 and the posterior segment of the 8th rib, with antialgic palliative purpose.

In the next two months, the patient presented considerable improvement of pain, and maintained supportive analgesic therapy.

In September 2017, the reassessment PET-CT revealed a heterogeneous response to vismodegib, with reduced metabolic activity of existing lesions and appearance of new lesions. In October 2017, the patient was admitted for symptomatic control of severe pain at the lumbosacral spine, refractory to analgesic therapy. In this context, segments L3-S3 were irradiated with 16 Gy in 4 fractions.

In November 2017, due to pain recurrence at the lumbar region, re-irradiation was performed to the L5-S3 segments, with 30 Gy in 10 fractions.

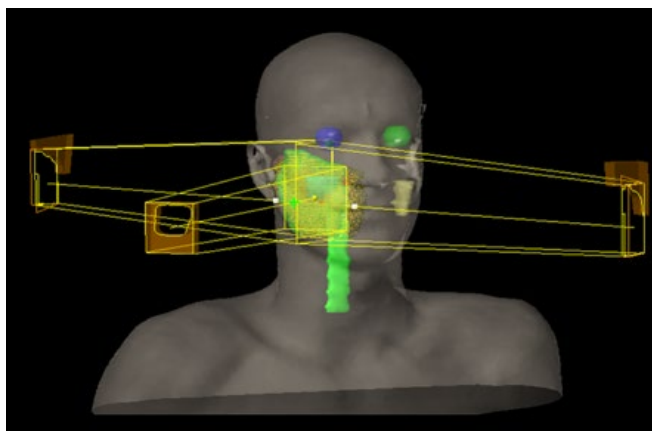
Due to a weak response to vismodegib, systemic therapy was changed by adding pembrolizumab (200 mg, each three weeks) in December 2017, and upon disease progression in the PET-CT, it was decided to suspend pembrolizumab in April 2018, and then start chemotherapy with cisplatin and 5-fluorouracil (six cycles, with partial, heterogeneous and symptomatic improvement). In May 2018, the patient also began denosumab (120 mg, once a month).

Subsequently, an incisional biopsy of a new centimetric nodular cutaneous lesion in the right arm revealed an infiltrative BCC metastasis (Figs 2a-b). The immunohistochemical staining showed that tumor cells were positive for CK5/6, p63, Ber-EP4 (Fig. 2c), and negative for CK20, thus supporting the diagnosis.

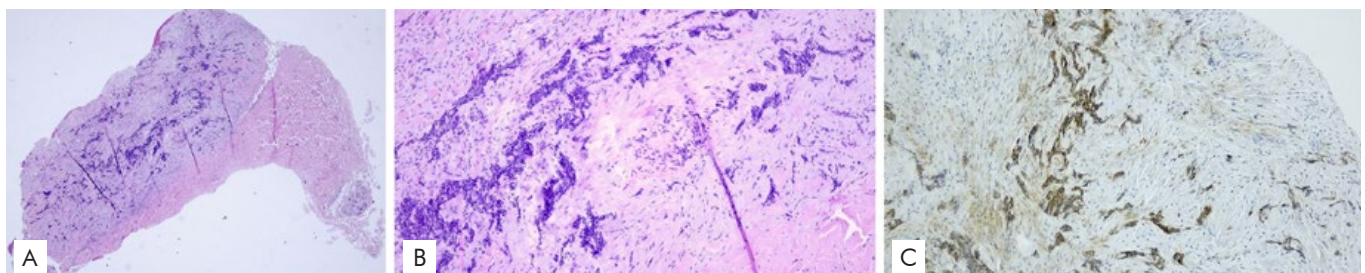
PET-CT performed in June 2019 revealed diffuse spreading bone metastases, the appearance of new cutaneous and subcutaneous metastases in the frontal region, and bilateral pulmonary micronodulation. The patient was then recommended to for a second line of chemotherapy with carboplatin and paclitaxel. However, in October 2019, PET-CT noticed the massive progression of bone and lung metastases (Fig. 3), and so it was decided to do a therapeutic switch to itraconazole (800 mg, once daily), discontinued three months later, due to poor response and adverse events, mainly fatigue.

By this time, the patient developed horizontal diplopia, with apparent paresia of the VI right cranial nerve. A magnetic resonance imaging of the skull showed metastatic infiltration of the clivus bilaterally, as well as an expansive lesion at the base of the left orbit.

Since November 2019, the patient maintained best supportive care, and died on December 23, 2019 - about 3 years after the diagnosis of metastatic disease and 8 years after the onset of the primary lesion.



**Figure 1** - Treatment plan for adjuvant external beam RT (3D-CRT) directed to the right hemiface.



**Figure 2** - Histological images of the cutaneous BCC metastasis (Haematoxylin and Eosin) 100x (a), 400x (b), demonstrating typical basaloid morphology, and immunohistochemistry for Ber-EP4 with intense positivity of the neoplastic cells (c).

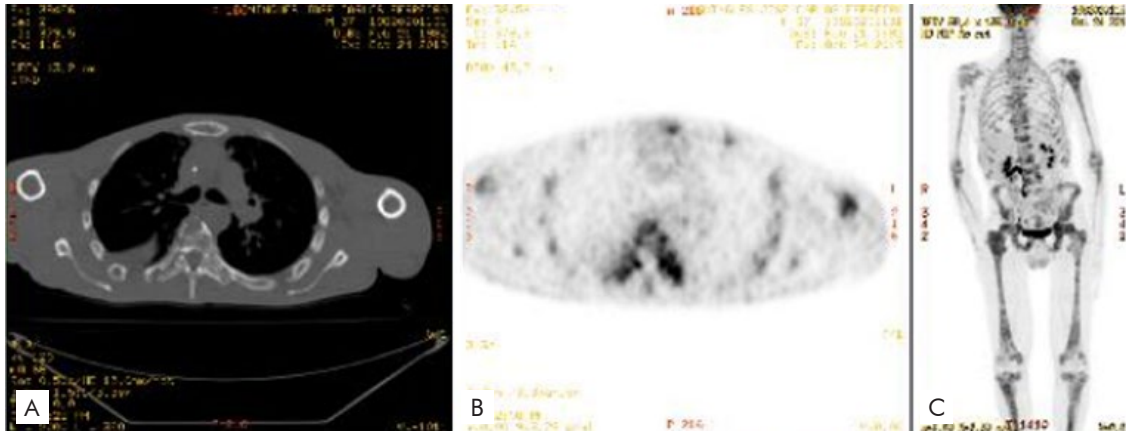


Figura 3 - Final PET/CT<sup>18</sup>F-FDG (October 2019): progression of bone and lung metastases.

## DISCUSSION

Although typically indolent, BCC can rarely metastasize at distance, considerably decreasing survival (10% at 5 years).<sup>7</sup>

Based on published reports between 1981 and 2011, McCusker *et al*<sup>8</sup> provided a review of 100 patients with advanced BCC, which revealed that distant metastases were diagnosed at a younger age (mean 58 years versus 66.3 years for regional metastases) and were associated with shorter overall survival time since diagnosis (24 versus 87 months). Bone metastases have been reported in 24% of patients with a median survival of 12 months (versus 26 months in patients without bone metastases). The McCusker *et al* review also mentions that the most common histological subtypes in primary tumors were, by this order of frequency, infiltrative, metatypical (basosquamous), and morpheiform.

Certain clinical and histopathological characteristics of BCC have been considered relevant for its probability to metastasize<sup>7,8</sup> and are recognized in this patient: male gender; young age of onset; location of the primary tumor on the head; short time interval between the onset of primary lesion and development of bone metastases; incomplete initial excision, with immediate healing; resistance to treatment.

Another contributing factor for distant metastases is local recurrence after surgical excision, especially when it is impossible to obtain free margins, which may result from the size and extent of the tumor.<sup>9</sup>

In the series of six cases of metastatic BCC, described by Lau *et al*,<sup>10</sup> the most common histological subtypes were morpheiform and infiltrative, which present an aggressive growth pattern. This fact was added to the presence of perineural and/or lymphovascular invasion in two of them, the first aspect also found in this case.

A curious fact in this case, is that there was no local recurrence of the primary lesion, after its re-excision and adjuvant external radiotherapy, which was also found in five of the six patients in the series of Lau *et al*.<sup>10</sup>

Post-operative external radiotherapy is associated with reduced risk of recurrence in high-risk patients, with local control rates of around 100%,<sup>11</sup> and is recommended after incomplete resection with microscopic (R1) or macroscopic (R2) residual tumour, if clear margins cannot be achieved, and also in patients with negative margins but evidence of considerable perineural involvement.

It should be noted that external radiotherapy represents a globally safe and well tolerated procedure, with improved cosmetic results.

Combination therapy between various modalities (chemotherapy,

targeted therapy, immunotherapy), in addition to external radiotherapy, is currently the standard of care in metastatic BCC.<sup>12</sup>

Recent developments on the immunological treatment of BCC have shown that inadequate signaling in the Hh pathway contributes significantly to the pathogenesis of a large percentage of localised and metastatic BCC.<sup>6</sup>

However, only two such Hh pathway inhibitors, vismodegib and sonidegib, are currently approved as systemic therapies for locally advanced and metastatic BCC.<sup>13,14</sup>

In this case, treatment recommended by the multidisciplinary team was vismodegib, an oral antagonist of the smoothed (SMO) protein involved in the Hh signaling pathway, investigated in a randomized phase II trial (ERIVANCE),<sup>13</sup> which showed a response rate of 30% and a median response duration of 7.6 months, in 33 patients with metastatic BCC. Clinical investigation into the efficacy of these therapeutic agents is still ongoing, with response rates ranging from 15% to 48.5% in advanced BCC.<sup>15-17</sup>

There is evidence that resistance to vismodegib may arise from mutations of the SMO protein or from downstream changes in the Hh pathway,<sup>18</sup> which could be an explanatory hypothesis in this case.

Furthermore, other pathways, such as the Wnt/ $\beta$ -catenin, interact with the Hh pathway. Therefore, investigating the cross-talk between those two signaling pathways, could be valuable in identifying better therapeutic strategies for advanced, inoperable and/or resistant BCC's.<sup>19</sup>

Chang *et al*<sup>20</sup> suggest that due to high levels of programmed death ligand-1 (PD-L1) expression in BCC, programmed death protein-1 (PD-1) inhibitors, such as pembrolizumab, may be a useful therapeutic option against advanced disease, especially when BCC is refractory to Hh pathway inhibitors.<sup>18</sup>

Unfortunately, in this patient treatment with anti-PD-1 pembrolizumab did not restrain BCC progression, which became an additional treatment challenge, since the mechanism of resistance by the bone metastasis to PD-1 inhibition is unclear and under ongoing investigation.<sup>18</sup>

Given the absence of an objective response, treatment with those targeted agents was discontinued and further management with chemotherapy was chosen. Due to the rarity of metastatic disease, information regarding chemotherapy is scarce, with reports on the use of platinum-based agents<sup>21</sup> and favorable responses described in 38% of the patients.<sup>8</sup>

Other known molecules, such as itraconazole, especially in cases of

resistance to SMO inhibitors, have shown efficacy, as demonstrated in an open-label, exploratory phase II trial.<sup>22</sup> However, our patient did not respond to itraconazole, which confirms the need for more studies and long-term follow-up for appropriate clinical evaluation in patients with refractory metastatic BCC.

## CONCLUSION

BCC is a very common tumor and the presence of metastases, although rare, should not be disregarded, as it implies high morbidity and mortality.

Due to the treatment and prognostic implications of metastatic BCC, it is essential to identify risk factors, in order to allow tighter surveillance of high-risk patients, with close clinical monitoring and serial imaging, and early implementation of adequate therapeutic strategies.

Follow-up of patients with BCC should include regular physical exams, including skin self-examination (6 – 12 months), particularly during the first two years, from which the frequency of the same can be reduced. A tighter and longer-term surveillance (for 3 – 5 years) should be adjusted to the risk of lesional recurrence (e.g., high-risk BCC patients, as is in the case of morpheaform histological subtype; patients already treated for recurrent BCC).

Histological/imaging tests to be performed should be selected according to the suspected disease extent (e.g., local, regional, metastatic), and may include biopsy for histological confirmation of local recurrence, CT scan (if suspected bone disease) or magnetic resonance imaging (MRI) (if perineural invasion, particularly for tumors on the head and neck).

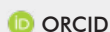In patients at high risk for multiple primary tumours (e.g., Gorlin syndrome; xeroderma pigmentosum) tighter surveillance is proposed, with skin examination every 4 – 6 months and, given the high risk of extracutaneous abnormalities, additional imaging (e.g., brain MRI, given the high risk of medulloblastoma).

Recent changes on the current standard for the systemic treatment of advanced BCC, emphasize the role of Hh signaling inhibitors as first-line agents, and suggest that immune checkpoint inhibitor-based immunotherapy may be effective in the treatment of this tumor.

In this case, the lack of efficacy of several combined therapeutic strategies turned into a clinical challenge. Advancing the research on the molecular pathology of this kind of unusual tumors will hopefully lead to more successful outcomes for future patients.

**Conflicts of Interest:** The authors have no conflicts of interest to declare. **Financing Support:** This work has not received any contribution, grant or scholarship. **Confidentiality of Data:** The authors declare that they have followed the protocols of their work center on the publication of data from patients. **Patient Consent:** Consent for publication was obtained. **Provenance and Peer Review:** Not commissioned; externally peer reviewed.

**Conflitos de Interesse:** Os autores declaram a inexistência de conflitos de interesse na realização do presente trabalho. **Fontes de Financiamento:** Não existiram fontes externas de financiamento para a realização deste artigo. **Confidencialidade dos Dados:** Os autores declaram ter seguido os protocolos da sua instituição acerca da publicação dos dados de doentes. **Consentimento:** Consentimento do doente para publicação obtido. **Proveniência e Revisão por Pares:** Não comissionado; revisão externa por pares.



Joana Calvão: <https://orcid.org/0000-0002-1161-269X>  
Ricardo Vieira: <https://orcid.org/0000-0002-5914-9171>

**Corresponding Author:** Luísa Rolim

**Address:** Department of Radiation Oncology, Coimbra University Hospital  
Praceta Prof. Mota Pinto 3004-561 Coimbra, Portugal  
**E-mail:** rolim.luisa@hotmail.com

© Author(s) (or their employer(s)) 2021 SPDV Journal. Re-use permitted under CC BY-NC. No commercial re-use.

© Autor (es) (ou seu (s) empregador (es)) 2021 Revista SPDV. Reutilização permitida de acordo com CC BY-NC. Nenhuma reutilização comercial.

## REFERENCES

- Freitas PP, Senna CG, Tabai M, Chone CT, Allemanni A. Metastatic basal cell carcinoma: a rare manifestation of a common disease. *Case Rep Med.* 2017;1-4. doi: 10.1155/2017/8929745.
- Nguyen-Nielsen M, Wang L, Pedersen L, Olesen AB, Mackey H, McCusker M, et al. The incidence of metastatic basal cell carcinoma (mBCC) in Denmark, 1997-2010. *Eur J Dermatol.* 2015;25:463-468.
- Snow SN, Sahl W, Lo JS, Mohs FE, Warner T, Dekkinga JA, et al. Metastatic basal cell carcinoma. Report of five cases. *Cancer.* 1994;73:328-35.
- von Domarus H, Stevens PJ. Metastatic basal cell carcinoma. Report of five cases and review of 170 cases in the literature. *J Am Acad Dermatol.* 1984;10:1043-60.
- Wysong A, Aasi SZ, Tang JY. Update on metastatic basal cell carcinoma: A summary of published cases from 1981 through 2011. *JAMA Dermatol.* 2013;149:615-6.
- Ascierto PA, Garbed C. Updates and new perspectives in nonmelanoma skin cancer from "Immunotherapy Bridge". *Immunotherapy.* 2020;12:167-74. doi: 10.2217/imt-2020-0042.
- Rodriguez C, Barrioso V, Chan LS. Extensive basal cell carcinoma with probable bone metastases. *Cutis.* 2007;80:60-6.
- McCusker M, Basset-Seguín N, Dummer R, Lewis K, Schadendorf D, Sekulic A, et al. Metastatic basal cell carcinoma: prognosis dependent on anatomic site and spread of disease. *Eur J Cancer.* 2014;50:774-83. doi: 10.1016/j.ejca.2013.12.013.
- Spates ST, Mellette JR Jr, Fitzpatrick J. Metastatic basal cell carcinoma. *Dermatol Surg.* 2003;29:650-652.
- Lau J, Guminski A, Gill A, Veivers D. Metastatic basal cell carcinoma: a review of six cases. *Aust J of Otolaryngol.* 2018;1:20.
- Han A, Ratner D. What is the role of adjuvant radiotherapy in the treatment of cutaneous squamous cell carcinoma with perineural invasion? *Cancer* 2007;109:1053-1059.
- National Comprehensive Cancer Network. Clinical Practice Guidelines in Oncology. Basal Cell Skin Cancer. Version 1.2021. Fort Washington: NCCN; 2021.
- Sekulic A, Migden MR, Oro AE, Dirix L, Lewis K, Hainsworth JD, et al. Efficacy and safety of vismodegib in advanced basal-cell carcinoma. *N Engl J Med.* 2012;366:2171-9. doi: 10.1056/NEJMoa1113713.
- Migden MR, Guminski A, Gutzmer R, Dirix L, Lewis KD, Combemale P, et al. Treatment with two different doses of sonidegib in patients with locally advanced or metastatic basal cell carcinoma (BOLT): a multicentre, randomised, double-blind phase 2 trial. *Lancet Oncol.* 2015;16:716-78. doi: 10.1016/S1470-2045(15)70100-2.
- Basset-Seguín N, Hauschild A, Grob JJ, Kunstfeld R, Dréno B, Mortier L, et al. Vismodegib in patients with advanced basal cell carcinoma (STEVIE): a pre-planned interim analysis of an international, open-label trial. *Lancet Oncol.* 2015;16:729-36. doi: 10.1016/S1470-2045(15)70198-1.
- Jacobsen AA, Aldahan AS, Hughes OB, Shah VV, Strasswimmer J. Hedgehog pathway inhibitor therapy for locally advanced and metastatic basal cell carcinoma: a systematic review and pooled analysis of interventional studies. *JAMA Dermatol.* 2016;152:8. doi: 10.1001/jama-dermatol.2016.0780.
- Sekulic A, Migden MR, Basset-Seguín N, Garbed C, Gesierich A, Lao CD, et al. Long-term safety and efficacy of vismodegib in patients with advanced basal cell carcinoma: Final update of the pivotal ERIVANCE BCC study. *BMC Cancer.* 2017;17:332. doi: 10.1186/s12885-017-3286-5.
- Cannon JGD, Russell JS, Kim J, Chang ALS. A case of metastatic basal cell carcinoma treated with continuous PD-1 inhibitor exposure even after subsequent initiation of radiotherapy and surgery. *JAAD Case Rep.* 2018;4:248-250.
- Noubissi FK, Yedjou CG, Spiegelman VS, Tchounwou PB. Cross-Talk between Wnt and Hh Signaling Pathways in the Pathology of Basal Cell Carcinoma. *Int J Environ Res Public Health.* 2018;15:1442. doi: 10.3390/ijerph15071442.
- Chang J, Zhu GA, Cheung C, Li S, Kim J, Chang AL. Association between programmed death ligand 1 expression in patients with basal cell carcinomas and the number of treatment modalities. *JAMA Dermatol.* 2017;153:285-90. doi: 10.1001/jamadermatol.2016.5062.
- Moeholt K, Aagaard H, Pfeiffer P, Hansen O. Platinum-based cytotoxic therapy in basal cell carcinoma-a review of the literature. *Acta Oncol.* 1996;35:677-82.
- Kim DJ, Kim J, Spauhurst K, Montoya J, Khodosh R, Chandra K, et al. Open-label, exploratory phase II trial of oral itraconazole for the treatment of basal cell carcinoma. *J Clin Oncol.* 2014;32:745-51. doi: 10.1200/JCO.2013.49.9525.