

IMAGE IN DERMATOLOGY

Asymptomatic Nodules in a Child

Nódulos Assintomáticos numa Criança

Received/Recebido
2021/04/07Accepted/Aceite
2021/07/25Published/Publicado
2021/12/30Regina Caldas¹ , Maria José Guimarães¹ , Joana Pardal² , Joana Gomes¹ ¹Department of Dermatology and Venereology, Hospital de Braga, Braga, Portugal²Department of Surgical Pathology, Hospital de Braga, Braga, Portugal**KEYWORDS** – Child; Mucinoses; Scleromyxedema.**PALAVRAS-CHAVE** – Criança; Escleromixedema; Mucínose.

A 4-year-old girl presented with multiple asymptomatic nodules on the back and lower limbs, which progressively appeared over the last year. Skin examination revealed more than ten, firm, erythematous to flesh-colored, grouped nodules, tending to coalesce, ranging 10-15 mm in diameter. They were asymmetrically distributed over the right lumbar region, left thigh (Fig. 1) and anterior aspect of legs. The patient's mother had similar lesions in the lumbar region and thighs, which had remained stable since childhood. Both were otherwise healthy.

Thyroid function, antinuclear antibodies and serum protein electrophoresis were unremarkable. Skin biopsy showed increased mucin deposition between collagen fibers in the mid and deep reticular dermis, with slight proliferation of fibroblasts (Fig. 2). Mucin stained positive with colloidal iron (Fig. 3), suggesting the diagnosis of nodular lichen myxedematosus.

Lichen myxedematosus (LM), also known as papular mucinosis, is characterized by lichenoid papules, nodules and plaques due to

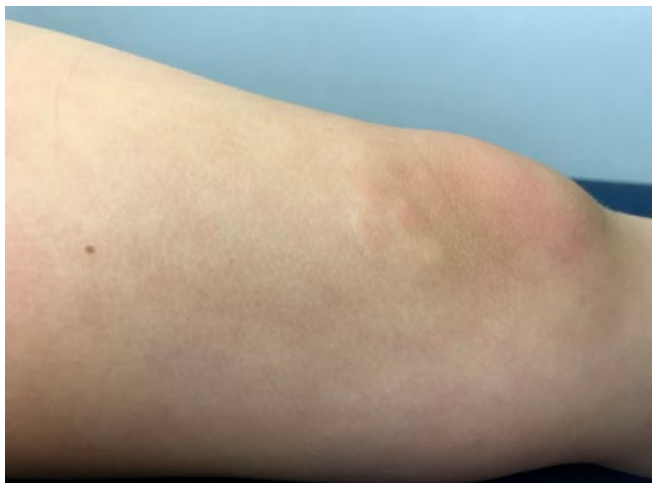


Figure 1 - Four grouped, erythematous nodules, with 10-15 mm in diameter, on the upper-inner aspect of the left knee.

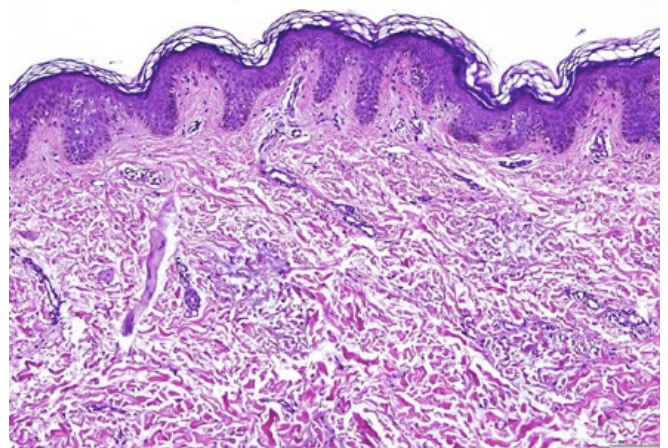


Figure 2 - Photomicrograph showing increased mucin deposition in dermis with separation of collagen fibers (hematoxylin and eosin, x100).

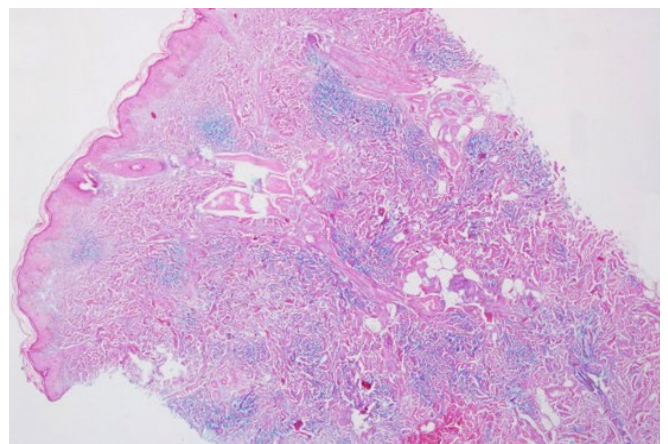


Figure 3 - Colloidal iron stain highlighting the interstitial deposition of mucin in reticular dermis (x40).

dermal mucin deposition and variable degree of fibrosis, without thyroid dysfunction.¹ It is uncommon in children.² LM is divided into two main clinicopathologic subsets: generalized papular and sclerodermoid form (scleromyxedema), associated with monoclonal gammopathy and systemic manifestations; and localized form, which presents no sclerotic features, paraproteinemia or systemic involvement.¹

Localized LM is further classified into: (1) discrete papular form, characterized by multiple symmetrically distributed, 2-5 mm, waxy papules on the trunk and limbs, that rarely resolve spontaneously; (2) acral persistent papular mucinosis, which develops exclusively on the dorsal aspect of the hands and extensor surface of the distal forearms, without spontaneous resolution; (3) cutaneous mucinosis of infancy, a pediatric variant of the two previous subtypes, occurring at birth or in the first months or years of life; and (4) nodular LM, characterized by multiple nodules on the limbs and trunk, with mild or absent papular component.¹⁻³

Histologic features of localized LM are less characteristic than those of scleromyxedema, with variable fibroblast proliferation and scarce fibrosis. Mucin deposits between collagen bundles can be highlighted with Alcian blue and colloidal iron stains. In acral persistent papular mucinosis, mucin accumulates focally in the upper dermis sparing a subepidermal zone, with a regular number of fibroblasts. In cutaneous mucinosis of infancy, mucin is very superficial, but a deeper involvement may occur in the nodular subtype.^{3,4}

Our case was diagnosed as nodular LM based on clinicopathological correlation, and absence of thyroid disorder, paraproteinemia or systemic manifestations. A limited number of small nodules randomly distributed on the lumbar region and lower limbs is not consistent with cutaneous mucinosis of infancy. Mucin deposition extending into the deep dermis also supports our diagnosis.

The pathogenesis of localized LM is unclear, without apparent relation to mucin production stimulated by autoantibodies, immunoglobulins, pro-inflammatory cytokines or infectious agents.^{1,2} In our case, clinical similarities between the mother and the patient's lesions raised the hypothesis of a familial association, although rare cases of familial localized LM have been described, suggesting a genetically mediated pathogenesis.^{3,5}

The differential diagnosis of nodular LM in childhood encompasses other dermatosis presenting with nodules or plaques, namely self-healing juvenile cutaneous mucinosis (SHJCM), collagenomas and subcutaneous granuloma annulare. SHJCM is another primary cutaneous mucinosis distinguished by an acute eruption of papules and nodules, with possible involvement of the face and periarticular areas, in addition to systemic symptoms and spontaneous resolution. A differentiating histologic feature of the latter is the remarkable increase in the number of fibroblasts, with bands of fibrosis.²

Treatment for localized LM is not required. Topical application of moderate to high potency corticosteroids or tacrolimus has been used with variable success,⁶ as well as local injections of triamcinolone acetonide or hyaluronidase.⁷ In our case, lesions stabilized without treatment after 1-year follow-up.

Presentations/Apresentações

This work has already been presented as an oral communication in the XIX Congress of the Portuguese Society of Dermatology and Venereology, 6-8th December 2019, Porto.

Conflicts of Interest: The authors have no conflicts of interest to declare. **Financing Support:** This work has not received any contribution, grant or scholarship. **Confidentiality of Data:** The authors declare that they have followed the protocols of their work center on the publication of data from patients. **Patient Consent:** Consent for publication was obtained. **Provenance and Peer Review:** Not commissioned; externally peer reviewed.

Conflitos de Interesse: Os autores declaram a inexistência de conflitos de interesse na realização do presente trabalho. **Fontes de Financiamento:** Não existiram fontes externas de financiamento para a realização deste artigo. **Confidencialidade dos Dados:** Os autores declaram ter seguido os protocolos da sua instituição acerca da publicação dos dados de doentes. **Consentimento do doente para publicação obtido.** **Proveniência e Revisão por Pares:** Não comissionado; revisão externa por pares.

ORCID

Regina Caldas: <https://orcid.org/0000-0002-6921-7916>
Maria José Guimarães: <https://orcid.org/0000-0002-3247-2470>
Joana Pardal: <https://orcid.org/0000-0002-4476-2889>
Joana Gomes: <https://orcid.org/0000-0002-3048-7193>

Corresponding Author: Regina Caldas

Address: Department of Dermatology and Venereology, Hospital de Braga Sete Fontes - São Victor, 4710-243 Braga, Portugal
E-mail: regina.mimed@gmail.com

© Author(s) (or their employer(s)) 2021 SPDV Journal. Re-use permitted under CC BY-NC. No commercial re-use.

© Autor (es) (ou seu (s) empregador (es)) 2021 Revista SPDV. Reutilização permitida de acordo com CC BY-NC. Nenhuma reutilização comercial.

REFERENCES

1. Rongioletti F. Lichen myxedematosus (papular mucinosis): new concepts and perspectives for an old disease. *Semin Cutan Med Surg.* 2006;25:100-4. doi: 10.1016/j.sder.2006.04.001.
2. Rongioletti F. Primary paediatric cutaneous mucinosis. *Br J Dermatol.* 2020;182:29-38. doi: 10.1111/bjd.18004.
3. Podda M, Rongioletti F, Greiner D, Milbradt R, Rebora A, Kaufmann R, et al. Cutaneous mucinosis of infancy: is it a real entity or the paediatric form of lichen myxoedematosus (papular mucinosis)? *Br J Dermatol.* 2001;144:590-3. doi: 10.1046/j.1365-2133.2001.04090.x.
4. Zeng R, Li M, Jiang Y, Liu W. Nodular lichen myxedematosus during childhood: a case report. *Pediatr Dermatol.* 2014;31:e160-3. doi: 10.1111/pde.12376.
5. Scheidegger EP, Itin P, Kempf W. Familial occurrence of axillary papular mucinosis. *Eur J Dermatol.* 2005;15:70-2.
6. Rongioletti F, Zaccaria E, Cozzani E, Parodi A. Treatment of localized lichen myxedematosus of discrete type with tacrolimus ointment. *J Am Acad Dermatol.* 2008;58:530-2. doi: 10.1016/j.jaad.2006.10.021.
7. Ogita A, Higashi N, Hosone M, Kawana S. Nodular-type lichen myxedematosus: a case report. *Case Rep Dermatol.* 2010;2:195-200. doi: 10.1159/000323148.