

## Carcinoma de Células Escamosas sobre Queratodermia Marginada Palmar

Heliana Freitas de Oliveira Góes<sup>1</sup>, Maria Claudia Almeida Issa<sup>1</sup>, Flávio Barbosa Luz<sup>1</sup>, Caren dos Santos Lima<sup>1</sup>, Márcia Kalil Aidé<sup>1</sup>, Mayra Carrijo Rochael<sup>1</sup>, Roberta Duarte Bezerra Pinto<sup>1</sup>

<sup>1</sup>Universidade Federal Fluminense, Niterói, RJ, Brazil

**RESUMO** – Queratodermia marginada palmar é caracterizada pela queratodermia em faixa, nos limites das partes dorsal e palmar, em disposição nas bordas cubital e radial em pacientes com intensa exposição solar. De acordo com a literatura, por si só, a queratodermia marginada palmar não é considerada uma lesão pré-maligna. Relatamos o primeiro caso de carcinoma de células escamosas ou carcinoma espinocelular sobre queratodermia marginada palmar em uma mulher de 57 anos.

**PALAVRAS-CHAVE** – Carcinoma de Células Escamosas; Mão; Neoplasias da Pele Queratodermia Palmar e Plantar.

## Squamous Cell Carcinoma on Marginal Palmar Keratoderma

**ABSTRACT** – Marginal palmar keratoderma is characterized by palmar keratoderma affecting the limits of the dorsal and palmar regions of ulnar and radial edges in patients with intense sun exposure. According to the literature it is not considered a pre-malignant lesion. Nevertheless, we report the first case of squamous cell carcinoma on marginal palmar keratoderma in a 57 year-old woman.

**KEY-WORDS** – Carcinoma, Squamous Cell; Hand; Keratoderma, Palmoplantar; Skin Neoplasms.

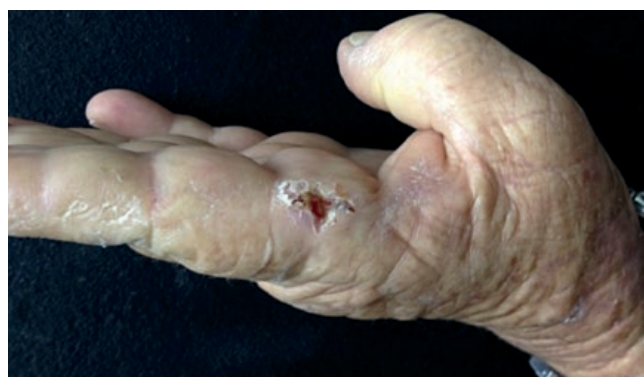### INTRODUCTION

Marginal palmar keratoderma (MPK), first described by Ramos e Silva,<sup>1</sup> is characterized by a particular palmar keratoderma localized on the limits of the dorsal and palmar regions of ulnar and radial edges of the hand, that occurs in patients with intense sun exposure. According to the literature it is not considered a pre-malignant lesion.<sup>2</sup> Therefore, the emergence of a squamous cell carcinoma (SCC) on this disease is unusual and, to our knowledge, this is the first case of SCC on MPK.

### CASE REPORT

A 57 year-old woman suffering from MPK localized on the ulnar edge of the hand for 10 years complained of a new lesion on the lateral side of the second left finger (on the area with keratodema), that had developed in the last two years. She denied trauma or pain at this site. She had a previous basal cell carcinoma from the dorsum of the nose excised in 2006. She worked as a housemaid, denied previous exposure to carcinogens such as arsenic and there was no HPV infection at the site of injury. On the dermatological exam, there was

an ulcer with erythematous border and keratotic areas, measuring 0.5 cm on the lateral side of the second finger, over MPK area (Fig. 1). Histopathology showed a well differentiated

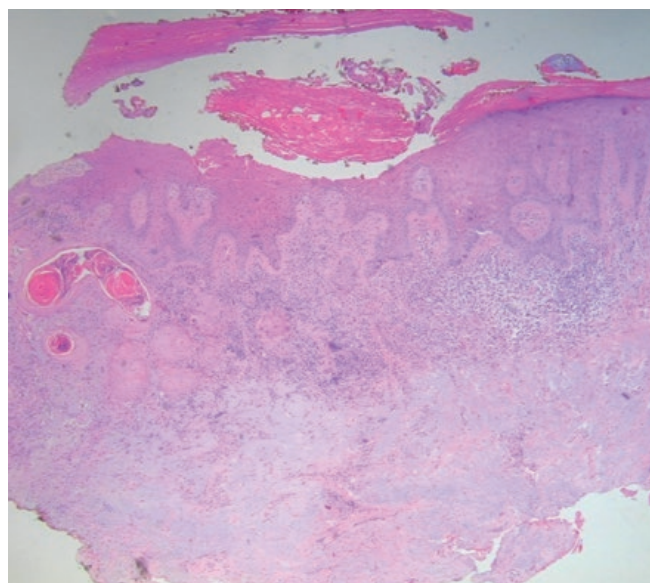


**Figure 1** - Ulcer with an erythematous border and keratotic areas on the side of the second finger on the area of palmar marginated keratoderma.

**Correspondência:** Heliana Freitas de Oliveira Góes  
Rua Itararé, 177, apto 96  
Bela Vista - São Paulo - SP, Brasil  
**E-mail:** heliana\_g@yahoo.com.br

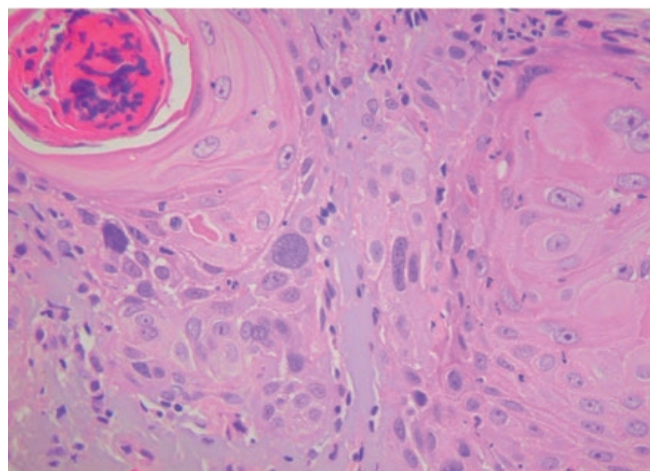
**Recebido/Received**  
20 Abril/20 April 2016  
**Aceite/Accepted**  
22 Maio/22 May 2016

## Caso Clínico



**Figure 2** - PWell-differentiated squamous cell carcinoma. Epidermal hyperplasia, area with atypical keratinocytes in the dermis and basal layer (H&E, x100).

SCC, represented by epidermal hyperplasia, an area with atypical keratinocytes in the basal layer and, in the dermis, nests of atypical squamous epithelial cells with keratin cornification in the center (Figs 2 and 3). Surgical excision was performed without complications and histopathological study showed tumor-free margins.



**Figure 3** - Nests of atypical squamous cells. Keratin pearls (H&E, x100).

### DISCUSSION

SCC is a malignant tumor derived from epidermal keratinocytes of the suprabasal layer, with invasive nature and potential for metastasis and is responsible for about 15% of cutaneous epithelial neoplasms. Most often, it develops from pre-malignant lesions that originate in regions of high solar elastosis, particularly actinic keratosis (97% of cases) and actinic cheilitis, as well as leukoplakia, radiodermatitis, arsenical keratosis, xeroderma pigmentosum, chronic ulcers, burn scars, oral erosive lichen planus, among others.<sup>3,4</sup> MPK is considered to be a consequence of chronic and recurring trauma, solar elastosis and local circulatory disorder.<sup>2</sup> Although MPK has not been considered a pre-malignant lesion in the current literature, our case had an intense solar exposure which is involved in the pathogenesis of both SCC and MPK, reinforcing a possible association between these two diseases: a pre-existing UV-induced dermatosis and the development of a SCC. Nevertheless, the association between MPK and SCC could be just fortuitous.

**Conflitos de interesse:** Os autores declaram não possuir conflitos de interesse. **Suporte financeiro:** O presente trabalho não foi suportado por nenhum subsídio ou bolsa. **Direito à privacidade e consentimento escrito:** Os autores declaram que pediram consentimento ao doente para usar as imagens no artigo.

**Conflicts of interest:** The authors have no conflicts of interest to declare. **Financing Support:** This work has not received any contribution, grant or scholarship. **Privacy policy and informed consent:** The authors declare that the patient gave written informed consent for the use of its photos in this article.

### REFERENCES

1. Ramos e Silva J. Queratodermia marginal das palmas. An Brasil DermatolSifilogr. 1957; 32:131-2.
2. Zanini M. Hiperkeratose focal acral: relato de caso e discussão sobre as ceratodermias marginais. An Bras Dermatol. 2006; 81:293-6.
3. Yanofsky VR, Mercer SE, Phelps RG. Histopathological variants of cutaneous squamous cell carcinoma: a review. J Skin Cancer. 2011; 2011:1-13.
4. Farasat S, Yu SS, Neel VA, Nehal KS, Lardaro T, Mihm MC, et al. A new American Joint Committee on Cancer staging system for cutaneous squamous cell carcinoma: creation and rationale for inclusion of tumor (T) characteristics. J Am Acad. Dermatol. 2011; 64:1051-9.