

Líquen Aureus Unilateral em Criança - Relato de Caso

Heliana Freitas de Oliveira Góes, Marília Troyano de Castro Mendes, Aline Falci Loures, Ada Lobato Quattrino, Caren dos Santos Lima, Luciana Pantaleão
Universidade Federal Fluminense, Niterói, RJ, Brazil

RESUMO – O líquen aureus é um subtipo de dermatose purpúrica pigmentada benigna, de curso crônico, de etiologia desconhecida. Apresenta predileção pelos membros inferiores e, em geral, afeta adultos jovens e, menos frequentemente, crianças. Relatamos um caso de líquen aureus de apresentação unilateral em criança.

PALAVRAS-CHAVE – Alterações da Pigmentação; Criança; Erupções Líquenóides; Perna.

Unilateral Lichen Aureus in a Child - Case Report

ABSTRACT – Lichen aureus is a subtype of a chronic benign pigmented purpuric dermatosis of unknown etiology. It shows predilection for lower limbs and generally affects young adults and, less often, children. We report a case of lichen aureus with a unilateral presentation in a child.

KEY-WORDS – Child; Leg; Lichenoid Eruptions; Pigmentation Disorders.

INTRODUCTION

Lichen aureus is a subtype of the chronic benign pigmented purpuric dermatosis of unknown etiology.^{1,2} It is an inflammatory disease with a chronic course characterized by macules, papules or patches with a lichenoid aspect and a variable color from brown to gold or erythematous-purplish.^{3,4} Usually lesions are bilateral, painless, although there are reports of unilateral, painful, zosteriform manifestations that become confluent, called agminate lichen aureus.⁵ It localizes preferentially to the lower limbs, although it can also affect the arms, hands and dorso. Generally it affects young adults and less frequently children.^{5,6} We report a case of unilateral lichen aureus in a child.

CASE REPORT

A 10-year-old female, Fitzpatrick skin type IV, living in Rio Bonito - Rio de Janeiro - Brazil, was referred to the Department of Pediatric Dermatology for painless hyperchromatic lesions on the right leg, close to the medial malleolus, with little itching, that had begun two years before. She had no other disease and did not use regular medications.

We observed several linear purplish-brown maculopapular lesions, with mild lichenification and a purpuric component near the medial right malleolus associated with macular pigmented lesions that extended along the leg to the knee (Fig. 1).

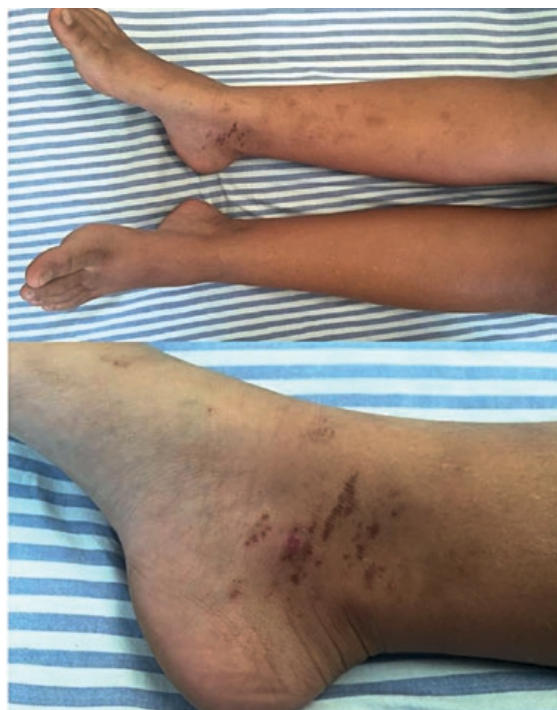

Figura 1 - Unilateral lesions of lichen aureus.

Correspondência: Heliana Freitas de Oliveira Góes
Rua Itararé, 177, apto 96. Bela Vista
São Paulo-SP, Brasil
E-mail: heliana_g@yahoo.com.br

Recebido/Received
19 Abril/19 April 2016
Aceite/Accepted
29 Maio/29 May 2016

Caso Clínico

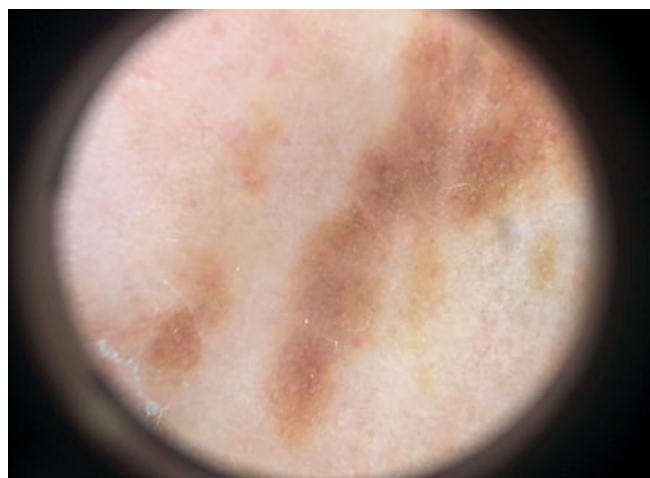


Figure 2 - Dermoscopy of lichen aureus showing an amorphous copper-colored area with no pigmented network.

Dermoscopy showed a copper-colored amorphous area with no pigmented network (Fig. 2). Histopathology of the biopsy taken from the medial malleolus showed chronic pigment purpura with hemosiderin deposits in the dermis and a lichenoid pattern compatible with the diagnosis of lichen aureus (Fig. 3).

Topical tacrolimus for 2 months had no effect on skin lesions. The patient was then lost to follow-up.

DISCUSSION

Lichen aureus is a rare pigmented purpuric eruption, distinguishable from others by having segmental distribution or isolated localized lesions, as in our patient.^{3,7} Although often bilateral, the unilateral distribution as in our case, was the predominant variant in a recently published Chinese series.⁵ Lichen aureus occurs most frequently in young adults with male predominance.^{1,3} In children, it tends to be self-limiting whereas in adults spontaneous resolution is rare, usually after years.^{1,2}

The etiology remains unknown, but studies suggest that it is associated with venous insufficiency, infection and/or drugs

such as pseudoephedrine and glipizide.^{1,2} The diagnosis of lichen aureus is fundamentally clinical and histopathological. The main histopathological changes are vacuolization of the basal layer of the epidermis, extravasated erythrocytes, a band-like lymphohistiocytic dermal infiltrate and hemosiderin deposition in macrophages,^{4,8} like in the present patient. Differential diagnosis should include other purpuric dermatoses, as well as nummular eczema, contact dermatitis, histiocytosis and traumatic purpura.^{1,3}

Treatment of lichen aureus is challenging but can be done with higher-potency corticosteroids, although there is little response. Moche *et al*,⁶ and Kim *et al*¹ reported cases of lichen aureus with a satisfactory response to methylprednisolone aceponate 0.1%. Topical pimecrolimus, psoralen plus ultraviolet radiation (PUVA) and, more recently, pulsed-dye laser can also provide some benefit.⁹

There are mostly old case reports that suggest an association between lichen aureus and mycosis fungoides (MF) in adulthood, as MF can also present with purpuric lesions and rare patients previously diagnosed as having lichenoid variants of persistent pigmented purpuric dermatitis have developed MF, with similar histopathologic findings and clonal lymphocytes. Therefore, monitoring of patients with lichen aureus was suggested, particularly in adult patients¹⁰ but recent studies with clinical and histopathologic follow-up of patients have not found such an association.¹¹

Conflitos de interesse: Os autores declaram não possuir conflitos de interesse. **Suporte financeiro:** O presente trabalho não foi suportado por nenhum subsídio ou bolsa. **Confidencialidade dos Dados:** Os autores declaram ter seguido os protocolos do seu centro de trabalho acerca da publicação dos dados de doentes.

Conflicts of interest: The authors have no conflicts of interest to declare. **Financing Support:** This work has not received any contribution, grant or scholarship. **Confidentiality of data:** The authors declare that they have followed the protocols of their work center on the publication of data from patients.

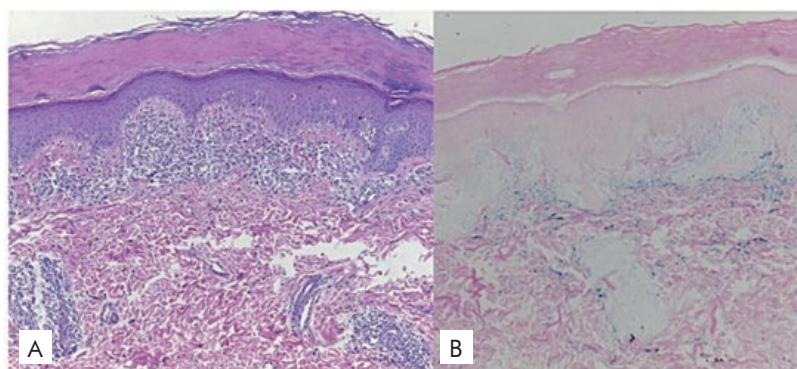


Figura 3 - A) Isolated necrotic keratinocytes, lichenoid infiltrate and extravasated erythrocytes (H&E, 100x). B) Dermal hemosiderin (blue) (Pearls; 100x).

REFERENCES

1. Kim MJ, Kim BY, Park KC, Youn SW. A case of childhood lichen aureus. *Ann Dermatol.* 2009; 21:393-5.
2. Hermoza Rodríguez J. Líquen aureus. *Dermatol Peru.* 2003; 13:220-2.
3. Cunha Filho RR, Schwartz J, Zanol J. Líquen aureus "algesiogênico". *An Bras Dermatol.* 2006; 81: 163-5.
4. Portela PS, Melo DF, Ormiga P, Oliveira FJ, Freitas NC, Bastos Júnior CS. Dermatoscopia do líquen aureus. *An Bras Dermatol.* 2013; 88: 253-5.
5. Tortelly VD, Silva RS, Mota ANCM, Piñeiro-Maceira J. Agminate Lichen Aureus. *An Bras Dermatol.* 2013; 88(6):143-5.
6. Moche J, Glassman S, Modi D, Grayson W. Segmental lichen aureus: a report of two cases treated with methylprednisolone aceponate. *Australas J Dermatol.* 2011; 52:e15-8.
7. Zeng YP, Fang K, Ma DL. Lichen aureus: clinicopathological features in a Chinese series. *Eur J Dermatol.* 2016 (*in press*)
8. Aung PP, Burns SJ, Bhawan J. Lichen aureus: an unusual histopathological presentation: a case report and a review of literature. *Am J Dermatopathol.* 2014; 36:e1-4.
9. Hong DK, Chang IK, Lee Y, Seo YJ, Kim CD, Lee JH, Im M. Treatment of segmental lichen aureus with a pulsed-dye laser: new treatment options for lichen aureus. *Eur J Dermatol.* 2013; 23:891-2.
10. Toro JR, Sander CA, LeBoit PE. Persistent pigmented purpuric dermatitis and mycosis fungoides: simulant, precursor, or both? A study by light microscopy and molecular methods. *Am J Dermatopathol.* 1997; 19:108-18.
11. Fink-Puches R, Wolf P, Kerl H, Cerroni L. Lichen aureus: clinicopathologic features, natural history and relationship to mycosis fungoides. *Arch Dermatol.* 2008;144:1169-73.