

## Sutura Tricofítica: Vantagens e Indicações Cirúrgicas

Ana Marta António<sup>1</sup>, Rui Oliveira Soares<sup>2</sup>

<sup>1</sup>Interna do Internato de Formação Específica em Dermatovenereologia, Serviço de Dermatovenereologia, Hospital Garcia de Orta, Almada, Portugal

<sup>2</sup>Assistente Hospitalar de Dermatovenereologia, Centro de Dermatologia, Hospital Cuf Descobertas, Lisboa, Portugal

**RESUMO** – Na cirurgia de transplante de cabelo, a par da preocupação com o resultado final na área transplantada, o resultado cosmético da área dadora tem merecido a atenção crescente do cirurgião de transplante capilar.

No transplante de unidade folicular a técnica de encerramento da área dadora tem evoluído no sentido de produzir cicatrizes progressivamente menos visíveis, mesmo em homens com cabelo curto. A sutura tricofítica é uma técnica que promove o crescimento de cabelo através da cicatriz final tornando-a menos visível. Esta técnica tem vindo a ser aperfeiçoada no transplante de unidade folicular mas tem também interesse no tratamento de cicatrizes e encerramento de feridas operatórias em outras áreas pilosas como o couro cabeludo, os supracílios e a barba. Os autores descrevem esta técnica cirúrgica, as suas vantagens e principais aplicações na cirurgia dermatológica.

**PALAVRAS-CHAVE** – Cabelo/transplantação; Cicatriz; Couro Cabeludo/cirurgia; Procedimentos Cirúrgicos Dermatológicos; Técnicas de Sutura.

## Trichophytic Suture: Advantages and Surgical Applications

**ABSTRACT** – In hair transplant surgery, the final cosmetic result of donor area has been a growing concern among hair transplant surgeons. In the follicular unit transplant, the closure technique of donor area has been improved in order to produce thin and virtually invisible scars even in males with short hair. Trichophytic closure is a special suture technique that allows hair to grow through the donor scar and make it less visible. This technique has been explored in the follicular unit transplant but is also very useful in treatment of imperfect old scars and closure of wounds in hair-bearing areas such as the scalp, eyebrows and beard. The authors describe this surgical technique, its advantages and applications in other dermatology surgeries.

**KEYWORDS** – Cicatrix; Dermatologic Surgical Procedures; Hair/transplantation; Scalp/surgery; Suture Techniques.

### INTRODUCTION

In the follicular unit transplantation (FUT) technique, in addition to the final appearance of the receiving area, the cosmetic result in the donor area is also important.

Virtually, any kind of hair transplant implicates permanent scars in the donor area. The patient naturally expects the transplant surgeon produces a thin, practically invisible linear scar, especially in male patients who are more likely to wear short hair.<sup>1</sup>

Classically, after removal of the hair bearing strip of skin from the back side, the wound is closed by stitches or staples. Even when the edges of the donor wound are

meticulously approximated by subcutaneous and cutaneous stitches and wound healing profile is propitious, the result is a linear scar with approximately 1-2 mm in width. This thin linear scar remains permanently in the donor area and may be more evident with short, wet or oiled hair. In some situations the scar may be wider or hypertrophic if patient's connective tissue is loose, if there is too much skin tension or if patient has a bad wound healing profile.<sup>1,2</sup>

The demand for more grafts has led hair transplant surgeons to perform wider strip excisions that produce proportionally more scarring due to skin tension.<sup>1</sup>

There are various closure techniques of the donor wound

**Correspondência:** Ana Marta António  
Serviço de Dermatovenereologia - Hospital Garcia de Orta  
Av. Torrado da Silva - 2801-951 Almada, Portugal  
**E-mail:** anamartaantonio@gmail.com

**Recebido/Received**  
26 Junho/June 2017  
**Aceite/Accepted**  
12 Julho/July 2017

## Dermatologia Cirúrgica

with different advantages and disadvantages. The one-layer running suture is simple and faster but does not reduce the tension when a donor strip is wide.<sup>3</sup> Subcuticular suture should be avoided because it is placed completely on upper dermis and could damage bulge region and compromise hair growth. In follicular unit transplantation surgery, a two-layers suture is the right choice in order to reduce tension and get a better cosmetic result.<sup>4</sup> Trichophytic closure is a special suture technique which allows hair to grow through the donor scar and make it less visible.<sup>5-7</sup>

In this manuscript the authors describe this suture technique, its main advantages in hair transplant surgery and other interesting applications in dermatologic surgery.

### TECHNIQUE

During removal of the hair bearing strip, the incision should be parallel to hair follicles to the full extent, and magnifying lenses are very useful to achieve this goal.

The subdermal space is closed with individual absorbable (3-0 vicryl) stitches placed on subcutaneous tissue/deep dermis every 2 cm, close enough to approximate the edges and far enough to minimize follicle damage.

Then, very carefully, the lower wound edge is trimmed by removing a thin strip of epithelium. Using surgical scissors or a scalpel a triangular strip is cut 1.0-1.5 mm wide at the lower edge (Fig.s 1 and 2A). Finally the superficial layer closure is performed with a running absorbable suture (3-0 vicryl rapid) (Fig. 2B). This technique places the superior wound edge over the inferior deepithelialized edge.

By this method, hair follicles below the cut edge will produce hair that grows normally through the future scar.

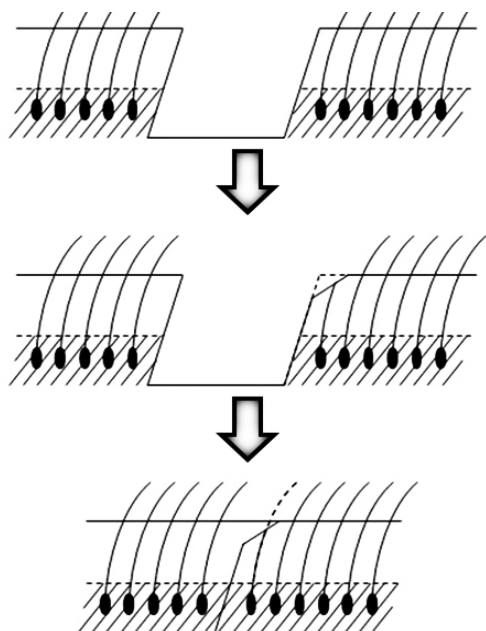


Figure 1 - Schematic illustration of the trichophytic suture.

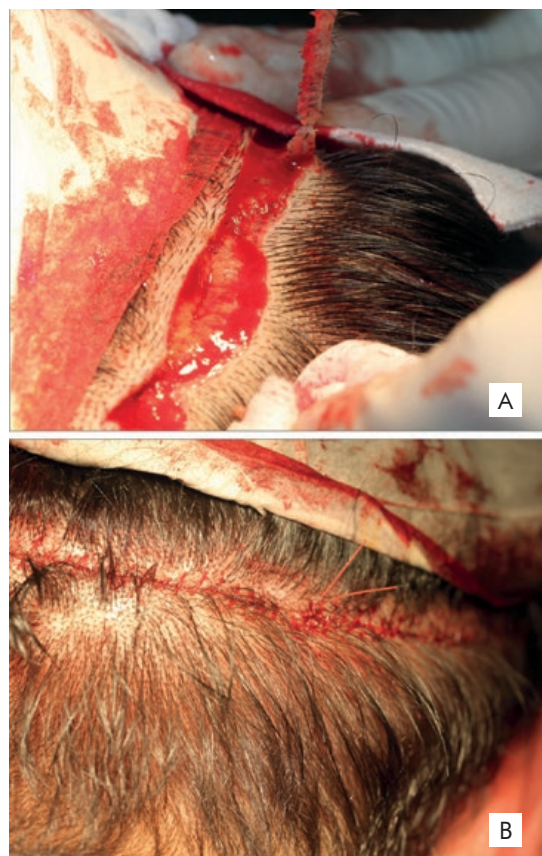


Figure 2 - A) lower wound edge after removing a thin strip of epithelium; B) immediate appearance of the scar after closing the superficial layer.

### ADVANTAGES AND SURGICAL APPLICATIONS

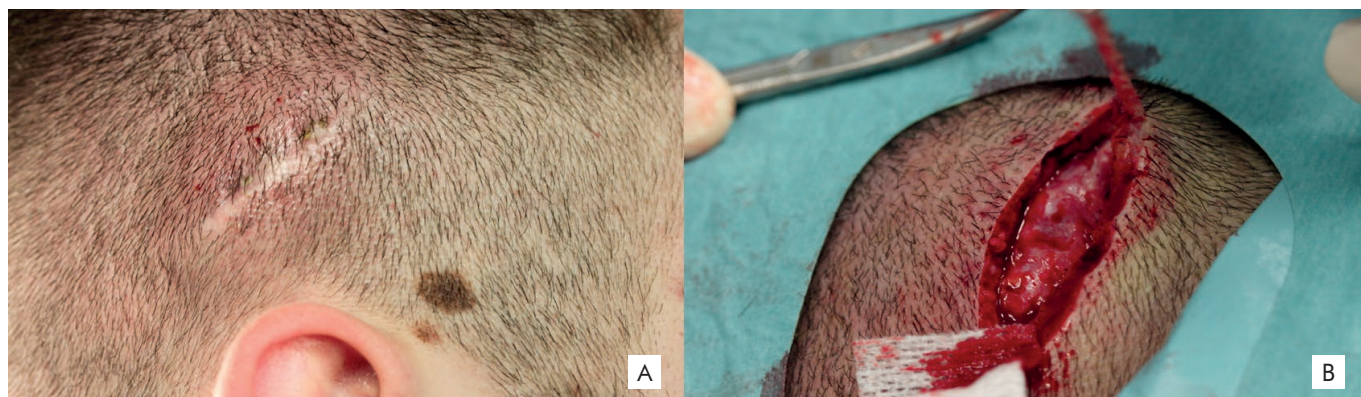This "tricho" closure technique induces hair growth through the incision line and may mask the final scar, making it invisible to the naked eye. In some cases a slightest difference in appearance could be noted because of the different direction of hair growth.

The irregular shape of deepithelialized edges and the pluripotential cells of follicle bulge probably contribute to improve the healing process.<sup>8,9</sup>

The trichophytic closure technique may be used in patients who underwent previous FUT treatment for the revision of the scar of the donor area making it less visible.

For patients with short haircuts this technique could offer a good alternative to Follicular Unit Extraction (FUE) in selected patients. The combination of both techniques could be a good option in cases where a greater number of grafts are required.

Apart from hair transplant surgery, the trichophytic suture could be an interesting option for closure of other wounds on hair-bearing areas, particularly on the scalp, brow and eyebrows and beard area in male patients.<sup>10-12</sup> In order to get a better cosmetic result it can be used to close traumatic wounds or incisions from dermatologic surgery and to correct older and unperfect scars (Fig.3).



**Figure 3** - A) Unightly scar of traumatic wound; B) Scar revision using trichophytic technique.

### CONCLUSION

The appearance of the donor area has been a growing concern for patients and hair transplant surgeons. We believe that this method is an excellent choice for closing and repairing donor wound in FUT in some selected patients, especially male patients. Beyond its usefulness in hair transplant surgery its principle justifies the use in other dermatological surgeries in hair bearing areas.

**Conflitos de interesse:** Os autores declaram não possuir conflitos de interesse.

**Suporte financeiro:** O presente trabalho não foi suportado por nenhum subsídio ou bolsa.

**Conflicts of interest:** The authors have no conflicts of interest to declare.

**Financing Support:** This work has not received any contribution, grant or scholarship.

### REFERENCES

1. Nirmal B, Somiah S, Sacchidanand SA. A study of donor area in Follicular Unit Hair Transplantation. *J Cutan Aesthet Surg.* 2013; 6:210-3.
2. Loganathan E, Sarvajnamurthy S, Gorur D, Suresh DH, Siddaraju MN, Narasimhan RT. Complications of hair restoration surgery: a retrospective analysis. *Int J Trichology.* 2014; 6:168-72.
3. Frechet P. Minimal scars for scalp surgery. *Dermatol Surg.* 2007; 33:45-55.
4. Kim CK, Kim DY, Kim JY. Asymmetric dermal-subdermal suture in trichophytic closure for wide hair transplantation donor wound. *Dermatol Surg.* 2013; 39:1124-7.
5. Frechet P. Donor harvesting with invisible scars. *Hair Transplant Forum Int.* 2005; 15:119-20.
6. Rose P. Presented a similar technique at the ESHRS meeting and writes. *Hair Transplant Forum Int.* 2005; 15:120.
7. Marzola M. Trichophytic closure of the donor area. *Hair Transplant Forum Int.* 2005; 15:113-6.
8. Ojeh N, Pastar I, Tomic-Canic M, Stojadinovic O. Stem cells in skin regeneration, wound healing, and their clinical applications. *Int J Mol Sci.* 2015; 16:25476-501.
9. Heidari F, Yari A, Rasoolijazi H, Soleimani M, Dehpoor A, Sajedi N, et al. Bulge hair follicle stem cells accelerate cutaneous wound healing in rats. *Wounds.* 2016; 28:132-41.
10. Holxomb JD, McCollough EG. Trichophytic incisional approaches to upper facial rejuvenation. *Arch Facial Plast Surg.* 2001; 3:48-53.
11. Owsley TG. Subcutaneous trichophytic forehead browlift: the case for an "open" approach. *J Oral Maxillofac Surg.* 2006; 64:1133-6.
12. Ahmad M. Does the trichophytic technique have any role in facial wound closure? A hypothesis. *J Plast Reconstr Aesthet Surg.* 2009; 62:662.