

Fotoquimioterapia no Eritema Anular Centrífugo Recalcitrante: Uma Opção Terapêutica Promissora?

Bruno Duarte¹, Filipa Rocha Páris¹, Joana Cabete¹

¹Dermatology Department, Hospital de Santo António dos Capuchos – Centro Hospitalar de Lisboa Central, Lisbon, Portugal

RESUMO – O eritema anular centrífugo, é uma dermatose de etiologia desconhecida e geralmente auto-limitada. Apesar disto, alguns casos tendem para a cronicidade, especialmente quando não é identificado o estímulo causal. Estes últimos casos são geralmente desafiantes do ponto de vista terapêutico.

Um homem de 24 anos recorreu à consulta de Dermatologia por placas policíclicas múltiplas, com crescimento radial, bordo infiltrado e clareamento central, localizadas nos glúteos, antebraços e coxas com 3 anos de evolução. A correlação clínico-patológica conduziu ao diagnóstico de eritema anular centrífugo. Foram excluídas causas secundárias. O tratamento com corticoides tópicos e sistémicos não ofereceu qualquer melhoria, e o doente estava relutante em tentar imunossuppressores sistémicos orais. Optou-se assim pela fotoquimioterapia. Uma melhoria muito significativa foi verificada desde o primeiro tratamento, ficando o doente completamente limpo ao sétimo tratamento. Aos 3 meses de *follow-up*, mantém-se em remissão.

No nosso conhecimento, relatamos o primeiro caso de eritema anular centrífugo tratado de forma bem-sucedida com fotoquimioterapia. Enfatizamos o papel que esta modalidade terapêutica clássica ainda pode, e deve ocupar no tratamento de dermatoses inflamatórias refratárias, como o eritema anular centrífugo.

PALAVRAS-CHAVE – Eritema/tratamento; Fotoquimioterapia.

Photochemotherapy for Recalcitrant Erythema Annulare Centrifugum: A Promising Treatment Option?

ABSTRACT – *Erythema annulare centrifugum* is a dermatosis of unknown aetiology which usually follows a self-limiting course. Nevertheless, some cases tend to chronicity, especially when a culprit stimulus is not found, and can be challenging to treat. A 24-year-old male presented with a 3-year history of persistent plaques with polycyclic outlines and an infiltrated rim on the forearms, buttocks and thighs. After histopathological correlation, a diagnosis of erythema annulare centrifugum was therein made. Secondary causes were ruled out. Treatment with topical and systemic steroids provided no benefit, and the patient was reluctant to further systemic oral immunosuppression. Photochemotherapy was then attempted. A marked improvement was observed since the first session, and the patient was clear by the 7th treatment. No adverse events were noted. The patient is still in remission at the 3rd month of follow-up.

To our knowledge, we report the first case of an erythema annulare centrifugum successfully treated with photochemotherapy. Our case highlights the potential of this time-honoured therapeutic modality to address chronic and debilitating cases of this figurate dermatosis.

KEYWORDS – Erythema/therapy; Photochemotherapy.

Correspondência: Bruno Duarte
Department of Dermatology
Hospital de Santo António dos Capuchos - Centro Hospitalar de Lisboa Central
Alameda Santo António dos Capuchos - 1169-050, Lisbon, Portugal
Tel.: +351213136300
E-mail: brunoduarte@campus.ul.pt
DOI: <https://dx.doi.org/10.29021/spdv.76.3.895>

Recebido/Received
25 Janeiro/January 2018
Aceite/Accepted
27 Abril/April 2018

Caso Clínico

INTRODUCTION

Erythema annulare centrifugum (EAC) is a figurate erythema which represents a delayed hypersensitivity reaction.^{1,2} In many cases the offending insult cannot be found and eliminated, leading to a chronic course for which effective therapies are lacking. Herein, we describe the complete resolution of a recalcitrant EAC using photochemotherapy, a long-established treatment in the dermatological armamentarium, yet unexplored for this purpose.

CASE REPORT

A 24-year-old, skin type III Caucasian male presented with a 3-year history of persistent, mildly pruritic plaques with polycyclic outlines and an infiltrated rim on the forearms, buttocks and thighs (Fig. 1A, 1C, 1E). The lesions began as small papules which expanded centrifugally through a leading edge, many of them with a trailing scale. Patient's medical past and general physical exam were unremarkable. Regular or sporadic use of medications was denied. A skin biopsy showed perivascular and periadnexal lymphocytic infiltrates with an acanthotic epidermis, parakeratosis, pityriasisform vesiculation and scant spongiosis (Fig. 2). Clinicopathological correlation established a diagnosis of EAC. An extensive laboratorial (blood cell count and differential, routine biochemistry, serum electrophoresis, protein count, viral serologies, erythrocyte sedimentation rate, thyroid panel, ANA and rheumatoid factor, stool tests for

bacterial, viral and parasitic pathogens, interferon gamma release assay for tuberculosis) revealed no abnormalities. Further investigation, including mycological and imaging tests were also unremarkable. Topical and systemic steroids were tried for a full year with little success and ensuing immediate relapses. Doxycycline 200 mg/daily provided mild benefit. The patient was reluctant to try oral or injectable immunomodulators. Treatment with psoralen ultraviolet-A (PUVA) twice weekly was then attempted (initial/final dose: 2.0/8.0J cm², respectively). A major improvement was progressively observed to a complete response on the 7th session (Fig. 1B, 1D, 1F). No side effects were observed. The patient was utterly satisfied. PUVA was stopped after the 20th treatment and no relapses have so far been observed on short follow-up (six months).

DISCUSSION

In many cases, EAC follows a self-limiting course. In others, a culprit stimulus can be found, either an infection, a drug, an underlying malignancy or any other disorder from a wide spectrum of putative associations.² Addressing the noxious stimuli usually leads to remission and hence is the therapy cornerstone. Albeit the apparent favourable prognosis, there is a subset of patients who follow a chronic, debilitating course for which symptomatic treatment is desired. Topical and systemic steroids are widely used, but long-term risks and relapses following discontinuation¹

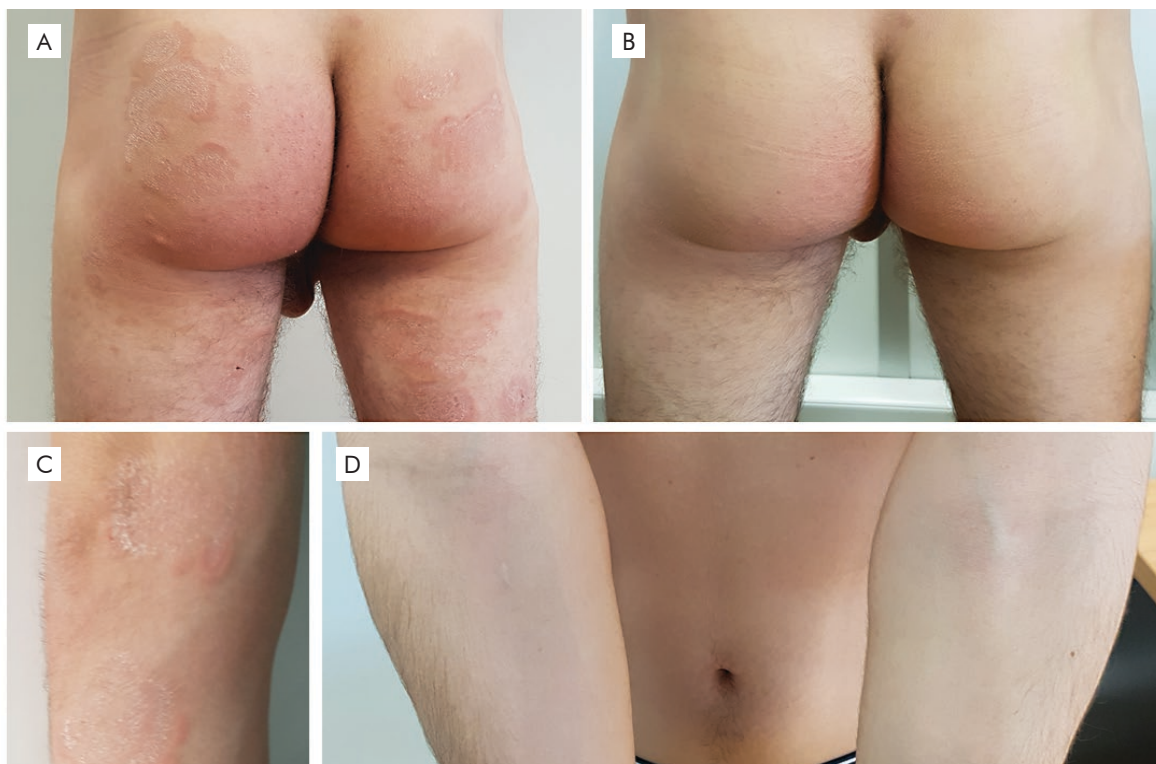


Figure 1

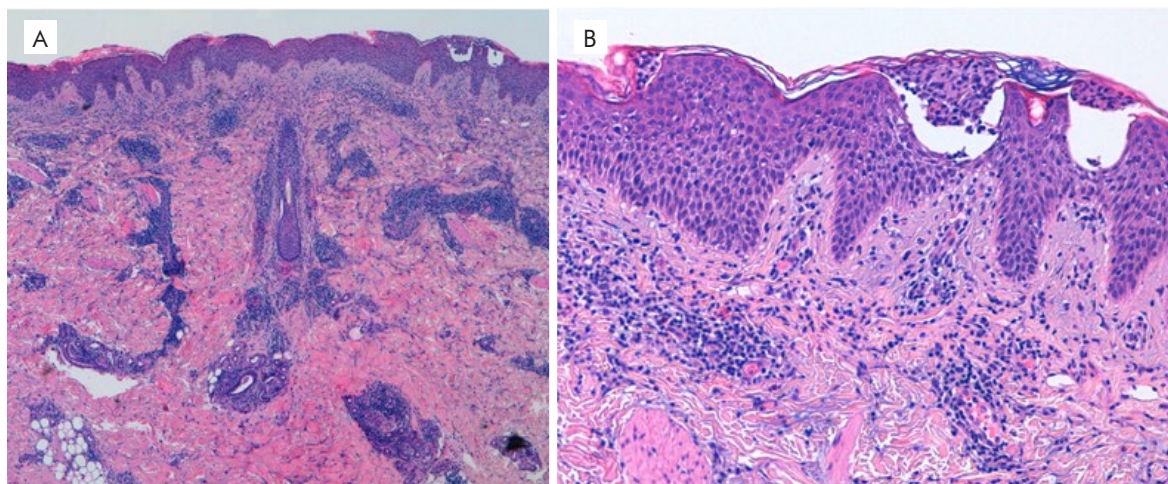


Figure 2

demand steroid-sparing therapeutic options. Consensus treatment guidelines are unfortunately inexistent for recalcitrant cases. Systemic immunomodulators are often given but may fail to provide relief.³ Erythromycin was reported as temporarily effective,¹ while a case documented a complete response with oral metronidazole⁴ and another case reported full remission with oral doxycycline therapy.⁵ Etanercept 25 mg biweekly induced complete clearance over a 6-month period in one patient.²

Phototherapy is a time-honoured therapeutic modality in many dermatological conditions,⁶ but evidence for its application in EAC is scarce. Narrow-band ultraviolet-B combined with calcipotriol ointment for 4-weeks led to remission in one case.⁷ Natural sunlight led to clearance in 2 cases.⁸ To our knowledge, this is the first report of a refractory, debilitating EAC case successfully managed with PUVA. A Th1-mediated pathogenesis has been speculated, in which tumour necrosis factor alfa (TNF- α) and associated cytokines play a critical role.² Indeed, inflammatory dermatoses are successfully treated by phototherapy through an interplay of photobiologic mechanisms,⁶ such as the down-regulating an overreactive, dysregulated Th1/Th17 axis and its orchestrated inflammatory cascade, including TNF- α .

We opted for photochemotherapy as, for this condition, it might be more effective than NB-UVB. Moreover, the twice-weekly PUVA regimen suited better the patient's busy schedule than its thrice-weekly NB-UVB, which reflected in a high-adherence rate. EAC histopathology often reveals dermal lymphocytic infiltrates, especially on its deep variant.⁹ Ultraviolet-A irradiation allows for deeper, mid- to deep-dermal immunomodulation¹⁰ which may superiorly target these immune cells. Furthermore, photochemotherapy leads to faster and longer lasting remission in other inflammatory cutaneous diseases.¹¹ Nevertheless, an unfavourable response to PUVA was previously reported in an isolated report,¹² albeit decisive therapeutic variables such

as treatment adherence and dose regimen were not included in the report.

In summary, the rapid resolution, excellent tolerability and sustained response makes PUVA an encouraging treatment for EAC. Despite a single report, we believe photochemotherapy should be further explored to ascertain the efficacy and long-term clearance rates of EAC with this promising and dermatologic-specific approach.

Conflitos de interesse: Os autores declaram não possuir conflitos de interesse.

Suporte financeiro: O presente trabalho não foi suportado por nenhum subsídio ou bolsa.

Confidencialidade dos dados: Os autores declaram ter seguido os protocolos do seu centro de trabalho acerca da publicação dos dados de doentes.

Protecção de pessoas e animais: Os autores declaram que os procedimentos seguidos estavam de acordo com os regulamentos estabelecidos pelos responsáveis da Comissão de Investigação Clínica e Ética e de acordo com a Declaração de Helsínquia da Associação Médica Mundial.

Conflicts of interest: The authors have no conflicts of interest to declare.

Financing Support: This work has not received any contribution, grant or scholarship.

Confidentiality of data: The authors declare that they have followed the protocols of their work center on the publication of data from patients.

Protection of human and animal subjects: The authors declare that the procedures followed were in accordance with the regulations of the relevant clinical research ethics committee and with those of the Code of Ethics of the World Medical Association (Declaration of Helsinki).

REFERENCES

1. Chuang F, Lin S, Wu W. Erythromycin as a safe and effective treatment option for erythema annulare centrifugum.

Caso Clínico

- Indian J Dermatol. 2015;60:519.
2. Minni J, Sarro R. A novel therapeutic approach to erythema annulare centrifugum. *J Am Acad Dermatol*. 2006;54(3 SUPPL. 2):134-5. doi:10.1016/j.jaad.2005.10.058.
 3. Phillips WG, Ramsay ID, Breathnach SM. Erythema annulare centrifugum unresponsive to immunosuppressive. *Br J Dermatol*. 1994;131:587.
 4. De Aloe G, Rubegni P, Risulo M, Sbrano P, Poggiali S, Fimiani M. Erythema annulare centrifugum successfully treated with metronidazole. *Clin Exp Dermatol*. 2005;30:583-4. doi:10.1111/j.1365-2230.2005.01796.x.
 5. Koh W, Liu T. Erythema annulare centrifugum: food for thought. *J Am Acad Dermatol*. 2015;72(Suppl 1):AB47. doi:10.1016/j.jash.2015.03.144.
 6. Nakamura M, Farahnik B, Bhutani T. Recent advances in phototherapy for psoriasis. *F1000Research*. 2016;5:1684. doi:10.12688/f1000research.8846.1.
 7. Reuter J, Braun-Falco M, Termeer C, Bruckner-Tuderman L. Erythema annulare centrifugum Darier. *Der Hautarzt*. 2007;58:146-8. doi:10.1007/s00105-006-1131-x.
 8. Colonel-Pérez I, Morillo-Andújar M. Erythema Annulare centrifugum responding to natural ultraviolet light erythema. *Actas Dermosiliogr*. 2010;101:177-8.
 9. Kim DH, Lee JH, Lee JY, Park YM. Erythema annulare centrifugum: Analysis of associated diseases and clinical outcomes according to histopathologic classification. *Ann Dermatol*. 2016;28:257-9. doi:10.5021/ad.2016.28.2.257.
 10. Vangipuram R, Feldman SR. Ultraviolet phototherapy for cutaneous diseases: A concise review. *Oral Dis*. 2016;22:253-9. doi:10.1111/odi.12366.
 11. Archier E., Devaux S, Castela E., et al. Efficacy of Psoralen UV-A therapy vs. Narrowband UV-B therapy in chronic plaque psoriasis: a systematic literature review. *J Eur Acad Dermatol Venereol*. 2012;26:11-21. doi:10.1111/j.1468-3083.2012.04519.x.
 12. Gniadecki R. Calcipotriol for erythema annulare centrifugum. *Br J Dermatol*. 2002;146:317-9. doi:10.1046/j.0007-0963.2001.04572.x.