

Dermatofibromas Eruptivos Múltiplos em Doente com Infecção pelo VIH

Alexandre Miroux-Catarino¹, Luís Soares-de-Almeida², João Borges-Costa^{2,3}

¹Médico Interno de Dermatovenereologia/Resident of Dermatology and Venereology, Serviço de Dermatologia, Centro Hospitalar de Lisboa Ocidental, Lisboa, Portugal

²Assistente Hospitalar de Dermatovenereologia / Consultant, Dermatology and Venereology, Centro Hospitalar Lisboa Norte; Professor Auxiliar Convidado de Dermatologia e Venereologia / Associated Professor, Dermatology and Venereology, Faculdade de Medicina da Universidade de Lisboa, Lisboa, Portugal

³Professor Auxiliar Convidado de Microbiologia / Professor, Microbiology, Instituto de Higiene e Medicina Tropical da Universidade Nova de Lisboa, Lisboa, Portugal

RESUMO – Dermatofibromas eruptivos múltiplos (DEM) é uma condição rara caracterizada pelo aparecimento de múltiplos dermatofibromas num curto período. DEM está habitualmente associada a alterações na imunidade e o seu diagnóstico deve levar a um rastreio adequado de patologias subjacentes, incluindo a infeção por VIH e lupus eritematoso. Reportamos um caso de DEM numa doente do sexo feminino VIH positiva, possivelmente associada à diminuição da contagem de linfócitos T CD4+ e aumento da carga viral.

PALAVRAS-CHAVE – Histiocitoma Fibroso Benigno; Infecções por VIH; Neoplasias da Pele.

Multiple Eruptive Dermatofibromas in a Patient with HIV infection

ABSTRACT – Multiple eruptive dermatofibromas is a rare event characterized by the appearance multiple dermatofibromas in few months. It is usually associated with immunodysregulation/immunosuppression. An appropriate work-up of underlying diseases must be done after this diagnosis, including search for HIV infection and lupus erythematosus. We present a case of multiple eruptive dermatofibromas in a female patient with HIV infection, possibly associated with a decrease in the CD4+ T cell count and viral load increase.

KEYWORDS – HIV Infections; Histiocytoma, Benign Fibrous; Skin Neoplasms.

INTRODUCTION

Dermatofibromas (DF) are benign fibrohistiocytic tumors, most often solitary not associated with internal disease, that usually appear on the legs of young women.¹ Multiple eruptive dermatofibromas (MEDF) is a rare event, first described by Baraf and Shapiro in 1970, characterized by the appearance of multiple lesions in a few months.^{2,3} The definition of MEDF is arbitrary, but is generally accepted as the presence of five to eight dermatofibromas in less than a 4-month period.⁴ The short period of time for the appearance of lesions is more important than the number of lesions.⁵ MEDF have been reported in the setting of autoimmune disease, patients treated with

immunosuppressive drugs and in the course of HIV infection or neoplasms.¹

CASE REPORT

A 42-year-old woman from Angola, Fitzpatrick type VI, known as HIV positive for 14 years, was observed with a 4-year history of several asymptomatic and hyperpigmented cutaneous lesions in the lower extremities, that appeared within a period of a few months. Examination of lower extremities revealed multiple dark-brown firm non-tender papules, with 2-8 mm in diameter (Fig.s 1 and 2). The “dimple sign” was demonstrated on each lesion. By consulting the clinical process it

Correspondência: Alexandre Miroux-Catarino
Serviço de Dermatologia - Hospital Egas Moniz
Rua da Junqueira 126
1349-019 Lisboa, Portugal
E-mail: alexandre_catarino@hotmail.com
DOI: <https://dx.doi.org/10.29021/spdv.76.3.902>

Recebido/Received
07 Fevereiro/February 2018
Aceite/Accepted
29 Março/March 2018

Caso Clínico

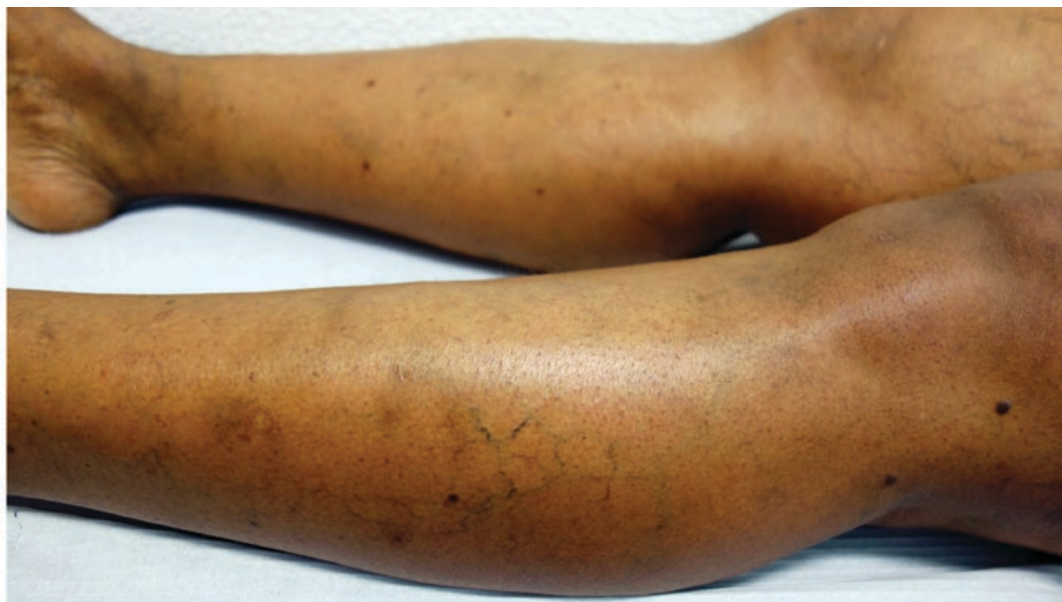

Figure 1 - Multiple dark-brown firm non-tender papules in the lower limbs, with 2-8 mm in diameter.

was possible to verify that when lesions began there was a decrease in the CD4⁺ T cell count (9 cells/mm³) and an increase in the viral load (454300 copies/mL). Afterwards, there was a change in the highly active antiretroviral therapy (HAART), with addition of dolutegravir to etravirine, ritonavir and darunavir. CD4 count increased to 174.6 cells/mm³, and at the moment

of the consultation there were 746.5 CD4⁺ cells/mm³ and the viral load was below the detection threshold.

The excisional biopsy showed a nodular dermal proliferation, predominantly of spindle-shaped fibroblasts and myofibroblasts arranged as short intersecting fascicles, consistent with dermatofibroma (Fig.s 3 and 4).

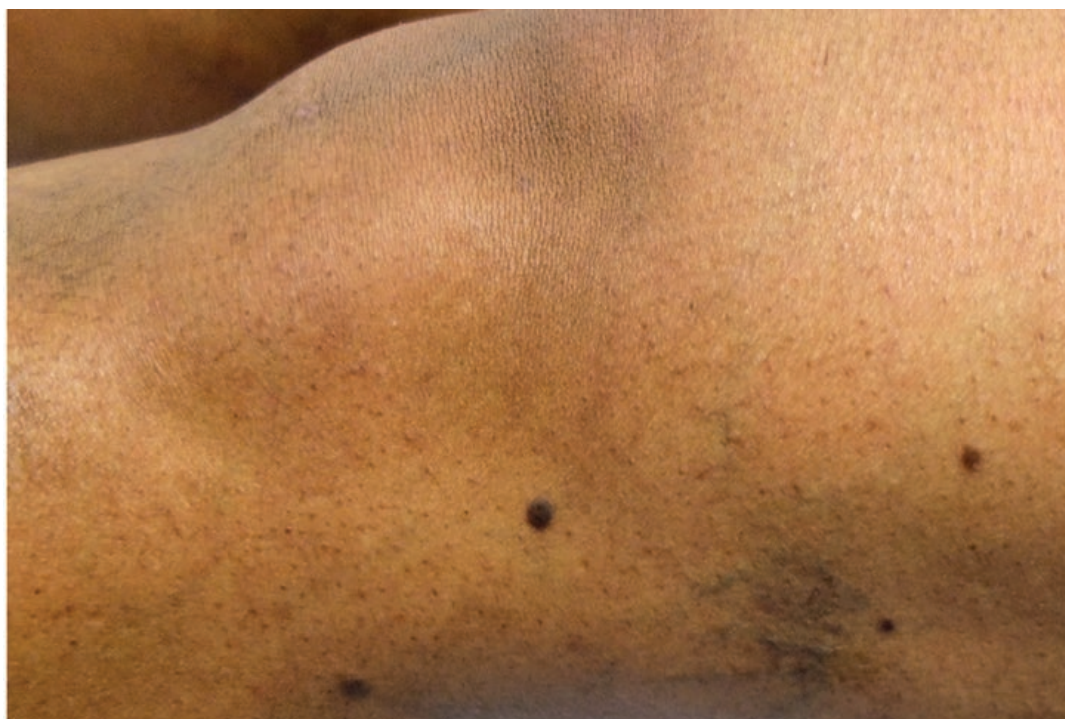

Figure 2 - Multiple dark-brown firm non-tender papules around the knee, with 2-8 mm in diameter.

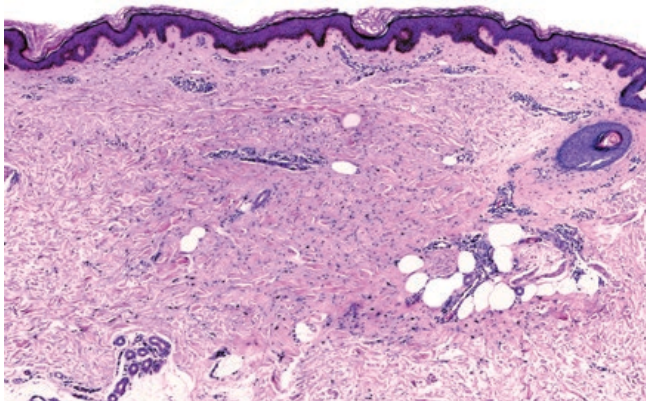


Figure 3 - Histopathology of the lesion. Nodular dermal proliferation, predominantly of spindle-shaped fibroblasts and myofibroblasts arranged as short intersecting fascicles. (H&E, 40x).

The combination of multiple dermatofibromas that appear in few months associated with an immune dysregulated status lead to the diagnosis of multiple eruptive dermatofibromas.

DISCUSSION

The clinical and histological features of MEDF did not differ from the solitary form. On histopathology the feature is similar to the solitary form, characterized by a well-circumscribed dermal tumour that is comprised of plump, spindle cells with collagen trapping at the outer edges of the lesion. Overlying epidermal hyperplasia and hyperpigmentation of the basal layer is frequent.

In addition to the number of dermatofibromas, the abrupt onset of lesions in a short period of time characterizes this diagnosis. MEDF are usually more prominent in legs, but may occur in other locations, including the hands.⁶ Comparing with classic dermatofibromas, MEDF extend more often to the trunk.⁷ MEDF are more frequent in immunosuppressed patients, but the number of dermatofibromas is variable and is not related with the rate of immunosuppression.² The condition is self-limiting and independent of the underlying disease evolution. The majority of patients have an underlying disease, and 66% of the cases are associated to immune-mediated diseases with systemic lupus erythematosus and HIV infection/AIDS among the more frequent associated pathologies.¹ Other associated diseases include dermatomyositis, Sjögren syndrome, myasthenia gravis, mycosis fungoides, hematologic malignancy, and medication, including: cyclophosphamide, methotrexate, glucocorticoids, azathioprine and anti-TNF- α . There are cases associated with changes in the HAART,⁸ yet it is questionable if it was consequence of the medication or consequence of an immune reconstitution. In our case, chronological evolution point to HIV infection as the associated condition. No new dermatofibromas appeared with the change in HAART. In the past, infectious agents have been proposed an etiologic factor for MEDF, in a context of immune reconstitution inflammatory syndrome.⁹ Recently it was proposed that dermatofibroma represents an

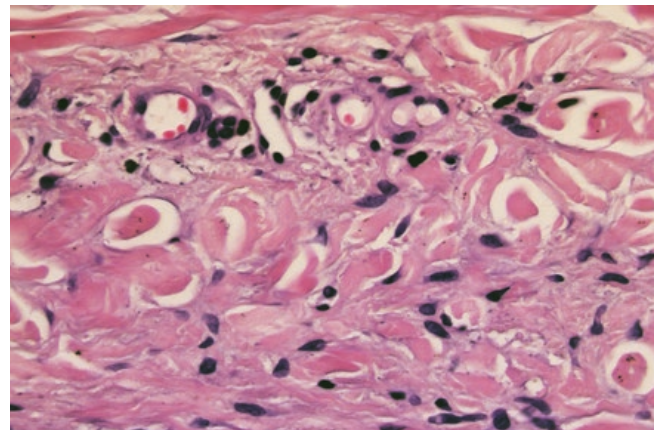


Figure 4 - Detail of histopathology showing plump spindle cells with collagen trapping. (H&E, 400x).

abortive immunoreactive process mediated by dermal dendritic cells. According to this hypothesis, development of MEDF in immunodeficiency states could be facilitated by the inhibition of down-regulatory T cells.¹⁰ In immunocompromised patients, the condition can be clinically confused with other papular lesions such as Kaposi's sarcoma and bacillary angiomatosis. The diagnosis of MEDF should be considered a consequence of immune dysregulation, and an appropriate work-up to rule out an autoimmune disorder, connective-tissue diseases, hematologic malignancies or HIV infection must be done.¹

Conflitos de interesse: Os autores declaram não possuir conflitos de interesse.

Suporte financeiro: O presente trabalho não foi suportado por nenhum subsídio ou bolsa.

Confidencialidade dos dados: Os autores declaram ter seguido os protocolos do seu centro de trabalho acerca da publicação dos dados de doentes.

Protecção de pessoas e animais: Os autores declaram que os procedimentos seguidos estavam de acordo com os regulamentos estabelecidos pelos responsáveis da Comissão de Investigação Clínica e Ética e de acordo com a Declaração de Helsínquia da Associação Médica Mundial.

Consentimento dos doentes: Obtido.

Conflicts of interest: The authors have no conflicts of interest to declare.

Financing Support: This work has not received any contribution, grant or scholarship.

Confidentiality of data: The authors declare that they have followed the protocols of their work center on the publication of data from patients.

Protection of human and animal subjects: The authors declare that the procedures followed were in accordance with the regulations of the relevant clinical research ethics committee and with those of the Code of Ethics of the World Medical Association (Declaration of Helsinki).

Patients consent: Obtained.

Caso Clínico

REFERENCES

1. Callahan S, Matires K, Shvartsbeyn M, Brinster N. Multiple eruptive dermatofibromas. *Dermatol Online J.* 2015;21: pii: 13030/qt69p1j0nj.
2. Zaccaria E, Rebora A, Rongioletti F. Multiple eruptive dermatofibromas and immunosuppression: report of two cases and review of the literature. *Int J Dermatol.* 2008;47:723-7.
3. Baraf CS, Shapiro L. Multiple histiocytomas. Report of a case. *Arch Dermatol.* 1970;101:588-90.
4. Ammirati CT, Mann C, Hornstra IK. Multiple eruptive dermatofibromas in three men with HIV infection. *Dermatology.* 1997;195:344-8.
5. Niiyama S, Katsuoka K, Happle R, Hoffmann R. Multiple eruptive dermatofibromas: a review of the literature. *Acta Derm Venereol.* 2002;82:241-4.
6. Chacon AH, Franca KL, Nouri K. Dermatofibromas eruptivos múltiples exclusivos de las manos. *Med Cutanea Ibero-Latina-Am.* 2014;42: 142-4.
7. Garcia-Millan C, Aldanondo I, Fernandez-Lorente M, Carrillo R, Jaen P. Dermatofibromas eruptivos múltiples asociados al virus de la inmunodeficiencia humana. Presentación de dos casos.. *Actas Dermosifiliogr.* 2007;98:702-6.
8. Bachmeyer C, Cordier F, Blum L, Cazier A, Verola O, Aractingi S. Multiple eruptive dermatofibromas after highly active antiretroviral therapy. *Br J Dermatol.* 2000; 143: 1336-7.
9. Silvestre JF, Betloch I, Jimenez MJ. Eruptive dermatofibromas in AIDS patients: a form of mycobacteriosis? *Dermatology.* 1997;194:197.
10. Kanitakis J, Carbonnel E, Delmonte S, Livrozet JM, Faure M, Claudy A. Multiple eruptive dermatofibromas in a patient with HIV infection: case report and literature review. *J Cutan Pathol.* 2000;27:54-6.