

# Necrólise Epidérmica Tóxica Induzida pelo Vemurafenib: Um Efeito Adverso Emergente

Ana Filipe Monteiro<sup>1</sup>, Margarida Rato<sup>1</sup>, César Martins<sup>2</sup>

<sup>1</sup>Interna do Internato de Formação Específica de Dermatovenereologia, Hospital de Santarém EPE, Santarém, Portugal

<sup>2</sup>Assistente Hospitalar Graduado de Dermatovenereologia, Hospital de Santarém EPE, Santarém, Portugal

**RESUMO** – O vemurafenib, um inibidor seletivo da mutação *BRAF V600*, está aprovado pela Food and Drug Administration (FDA) e European Medicines Agency (EMA) para o tratamento de melanoma metastático em estadio IV isoladamente ou em combinação. De entre os efeitos adversos, a toxicidade cutânea é a mais comum. A maior parte destas reações, como o eritema, a fotossensibilidade e as lesões hiperqueratósicas, são facilmente controladas podendo a maioria dos doentes continuar terapêutica. Contudo, têm sido descritos alguns casos de reações cutâneas graves com risco de vida e necessidade de suspensão terapêutica. Os autores reportam um caso de necrólise epidérmica tóxica induzida pelo vemurafenib num doente a efetuar tratamento para melanoma metastizado. Após várias complicações hospitalares, o doente sobreviveu à reação provocada pelo fármaco e encontra-se em remissão há 2 anos.

**PALAVRAS-CHAVE** – Antineoplásicos/efeitos adversos; Melanoma/tratamento; Síndrome de Stevens-Johnson/etiologia; Vemurafenib.

## Vemurafenib-Induced Toxic Epidermal Necrolysis: An Emerging Adverse Event

**ABSTRACT** – Vemurafenib, a selective inhibitor of the *BRAF V600* mutation, is Food and Drug Administration and European Medicines Agency approved for the treatment of stage IV metastatic melanoma alone or in combination. Among the adverse effects, cutaneous toxicity is the most common. Most of these reactions such as maculopapular rash, photosensitivity and hyperkeratotic lesions are manageable, and the majority of patients are able to continue therapy. However, a few cases of life-threatening severe cutaneous adverse reactions have been reported and drug withdrawal is mandatory in these cases. Herein, we report a case of vemurafenib-induced toxic epidermal necrolysis in a patient receiving therapy for metastatic melanoma. After several hospital complications, our patient survived to the drug-induced reaction and he is in remission for 2 years.

**KEYWORDS** – Antineoplastic Agents/adverse effects; Melanoma/drug therapy; Stevens-Johnson Syndrome/etiologia; Vemurafenib.

### INTRODUCTION

The selective *BRAF* inhibitor vemurafenib was approved by the Food and Drug Administration (FDA) and European Medicines Agency (EMA) for the treatment of metastatic or unresectable melanoma with *BRAF V600* mutation. It significantly increases the response rate, prolonged progression-free and overall survival in melanoma patients with *BRAF* mutation.<sup>1</sup> Initially it was approved as monotherapy, nowadays it is used in combination with a MEK inhibitor. However, the promising efficacy of this drug needs

to be considered against the potential adverse side effects during treatment. Drug-induced skin reactions are well known common side effects of vemurafenib therapy, including skin rash, phototoxicity and keratotic hyperproliferative lesions.<sup>2</sup> Most of these reactions are manageable, and the majority of patients are able to continue therapy. However, more serious adverse reactions (grade 4) are rarely described in literature and require drug suspension limiting the use of vemurafenib.

**Correspondência:** Ana Filipe Monteiro

Hospital de Santarém, EPE

Avenida Bernardo Santareno

2005-177 Santarém, Portugal

**Email:** anafilipemonteiro@gmail.com

**DOI:** <https://dx.doi.org/10.29021/spdv.76.3.926>

**Recebido/Received**

03 Abril/April 2018

**Aceite/Accepted**

13 Junho/June 2018

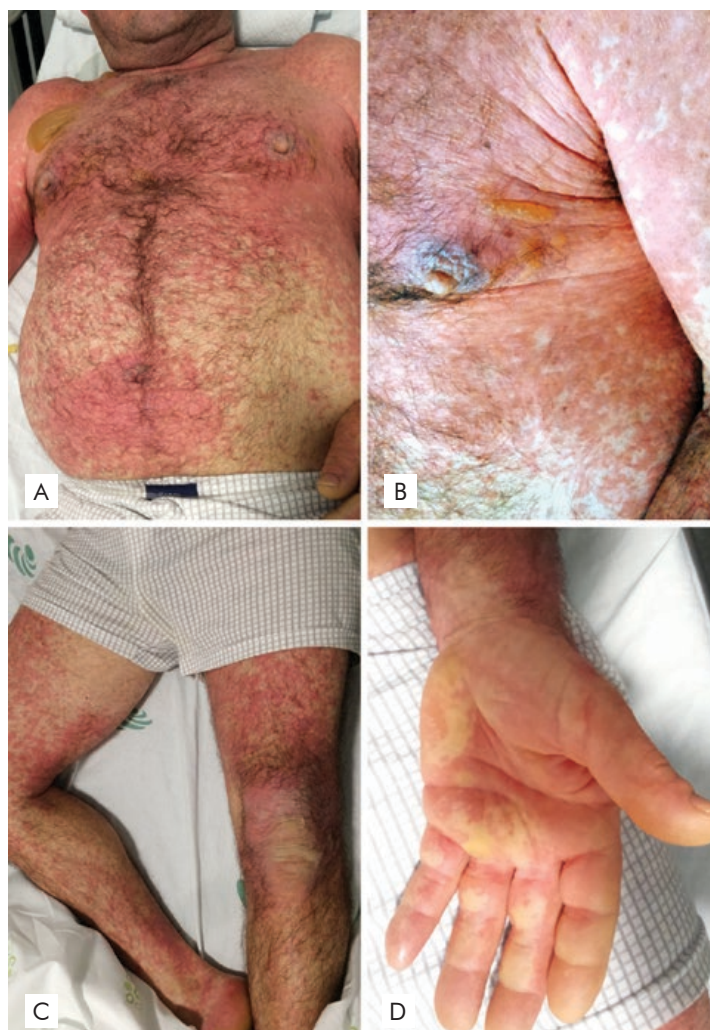## Caso Clínico

### CASE REPORT

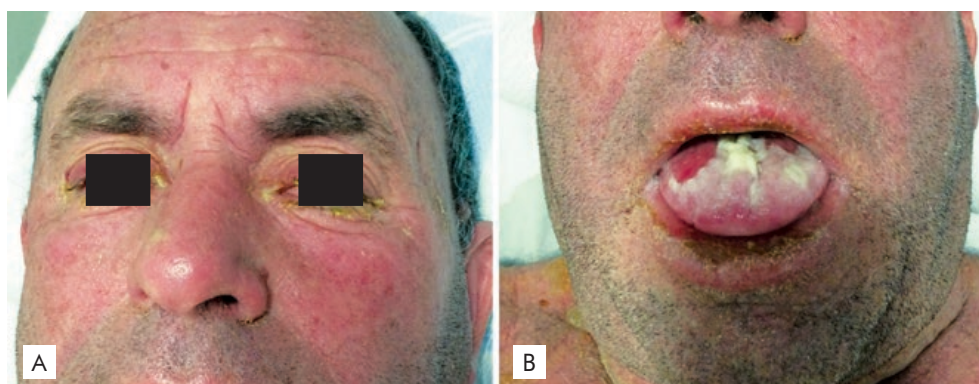
A 47-year-old man was diagnosed with superficial spreading left lumbar melanoma (Breslow thickness 2,15 mm, without ulceration, Clark level III) in May 2008 and positive sentinel lymph node biopsy. He underwent left inguinal lymphadenectomy for micrometastasis (1N+/7N). There was no relevant past history or medication use. The complete computed tomography scan (CT-scan) did not show any suspected metastatic lesions. The patient was staged as T3aN1aM0 and interferon alpha-2b (10MU three times per week) was administered subcutaneously during 1 year. Five years later, he presented with in-transit metastases in the left flank and iliac fossa that were excised. The complete CT-scan also revealed three new micronodules (< 5 mm) in the right lower lobe and two micronodules in the left upper lobe of the lung. These new findings were considered metastatic lesions, although histological confirmation was not possible due to their small size. Mutation analysis (cobas® 4800 BRAF V600

Mutation Test; Roche Diagnostics Limited) of a metastatic subcutaneous node showed a *BRAF* V600E mutation, and the patient was offered vemurafenib 960 mg twice daily. Serum lactate dehydrogenase level at this time was 171 U/L (normal range 125-220).

Eight days later, the patient developed a grade 2 maculopapular rash (Common Terminology Criteria for Adverse Events version 4.0 of the National Cancer Institute), initially restricted to lower limbs, associated to high fever (39.3°) and pruritus. During the following three days, the skin lesions progressed to widespread erythema with blisters involving head, trunk, arms and limbs (Fig. 1). Bilateral conjunctivitis, large erosions and ulceration of the oral mucosa were observed (Fig. 2). Laboratory investigations showed just a mild increase in liver aminotransferases (two times normal). The patient denied taking any other drugs. On clinical assessment, SCORTEN (SCORE of Toxic Epidermal Necrolysis) was calculated as 3, predicting a mortality rate of > 35%. The ALDEN



**Figure 1** - Erythema with blistering and epidermal detachment involving the trunk (A,B). Skin lesions progressed to widespread erythema with blisters involving arms and limbs (C, D).



**Figure 2** - Widespread erythema of the face with bilateral conjunctivitis (A). Cheilitis, large erosions and ulceration of the lips and tongue (B).

(Algorithm of Drug causality for Epidermal Necrolysis) score for vemurafenib was calculated as 5 (probable) and Naranjo score as 6 (probable). Vemurafenib was withdrawn, supportive treatment with prednisolone 1 mg/kg/day was started and he was immediately transferred to an intensive care unit. During the next 72 hours, lesions progressed to affect 90% of total body surface and mucosal sloughing in the upper airway. Intravenous immunoglobulin (IV Ig) was started at the dose of 1.5 mg/kg over 3 days. Re-epithelialization was slow, and therefore further 3 days of IV Ig at the same dose were prescribed. After 2 months of multiple complications in the intensive care unit, the patient was transferred back to the dermatology ward.

After this episode the patient has been submitted to a continuous follow-up. The patient has been on clinical and radiological remission. The complete CT-scan one and two years after the episode showed lung parenchyma without new lesions and no increase of the lung micronodules in comparison to the first CT-scan.

## DISCUSSION

Vemurafenib is a selective inhibitor of the *BRAF* V600 mutation approved for stage IV metastatic melanoma.<sup>1</sup> Among the adverse effects, cutaneous toxicity is the most common, affecting more than 90% of patients.<sup>2</sup> It is rarely severe, with 15% - 40% of grade 3 and less than 1% of grade 4 toxicities reported in literature.<sup>1,3</sup> Skin rash induced by vemurafenib was the most commonly reported adverse effect with a frequency in clinical trials ranging from 36% to 68%.<sup>2,4</sup> Skin rash usually occurred on the face, neck, trunk, and extremities and appeared with a mean time of 1.6 weeks after vemurafenib treatment.<sup>2</sup> However, serious cutaneous adverse events such as Stevens-Johnson syndrome, toxic epidermal necrolysis (TEN), cellulitis, drug reaction with eosinophilia and systemic symptoms (DRESS) are rare and a mandatory condition to drug discontinuation.<sup>2</sup>

Although a rare reaction in clinical practice, TEN has already been described in BRIM-3 study.<sup>5</sup> In the literature, toxic epidermal necrolysis due to vemurafenib was described in 6 case reports in the last 4 years (Table 1).<sup>6-11</sup> Some authors believe

**Table 1** - Summary of the characteristics of cases reported in the literature with TEN after vemurafenib.

Case	Year	Gender	Age	Onset of rash (days after starting vemurafenib)	Treatment performed for TEN	Other Melanoma therapy before vemurafenib	Evolution / Follow up
Wantz <i>et al</i> <sup>8</sup>	2013	F	75	21	Systemic corticotherapy	No	Died of disease progression
Sinha <i>et al</i> <sup>6</sup>	2014	F	73	15	Intravenous immunoglobulin	Not mentioned	Died of multiorgan failure
Jeudy <i>et al</i> <sup>7</sup>	2015	M	60	10	Not mentioned	Interferon alpha-2b	Switch to dabrafenib
Lapresta <i>et al</i> <sup>9</sup>	2015	M	68	28	Intravenous ciclosporin	No	Switch to ipilimumab
Arenbergerova <i>et al</i> <sup>10</sup>	2017	F	63	10	Intravenous corticotherapy	Nivolumab	Died of disease progression
Kılıç <i>et al</i> <sup>11</sup>	2017	M	69	15	Intravenous corticotherapy + immunoglobulin	Interferon alpha-2b	Died of sepsis
Our case	2017	M	47	8	Intravenous corticotherapy + immunoglobulin	Interferon alpha-2b	Complete remission

## Caso Clínico

that immune checkpoint inhibition by ipilimumab or nivolumab may predispose patients to drug hypersensitivity reactions due to strong activation of CD8<sup>+</sup> cells.<sup>10</sup> Concerning interferon alpha, it has been associated with a transient and mild generalized rash-like reaction but there is no severe cutaneous reactions reported.<sup>12,13</sup> Nevertheless, our case occurred from the isolated use of vemurafenib without previous checkpoint inhibitor drugs.

This case highlights the importance of careful patient monitoring, with particular attention to the development of skin rash with signs of severity within 2 weeks after vemurafenib initiation, such as epidermal detachment or mucosal involvement.<sup>3</sup>

Furthermore, a recent retrospective cohort study has shown for the first time a significant increase in overall survival in patients with severe toxicity emerging within the first 4 and 8 weeks on vemurafenib.<sup>3</sup> An explanation could be that the cutaneous drug reaction severity is the result of a strong activation of the innate immunity inducing a synergistic effect with vemurafenib against melanoma cells. However, this statement has to be confirmed in further studies with larger cohorts of patients. Fortunately, our patient survived to the drug-induced reaction and he did not present new in-transit metastasis since the drug reaction. He is in clinical and radiological remission for 3 years. If there is a future disease progression, drug switching to dabrafenib and trametinib appears to be a useful alternative treatment option.<sup>7</sup>

**Conflitos de interesse:** Os autores declaram não possuir conflitos de interesse.

**Suporte financeiro:** O presente trabalho não foi suportado por nenhum subsídio ou bolsa.

**Confidencialidade dos dados:** Os autores declaram ter seguido os protocolos do seu centro de trabalho acerca da publicação dos dados de doentes.

**Protecção de pessoas e animais:** Os autores declaram que os procedimentos seguidos estavam de acordo com os regulamentos estabelecidos pelos responsáveis da Comissão de Investigação Clínica e Ética e de acordo com a Declaração de Helsínquia da Associação Médica Mundial.

**Consentimento dos doentes:** Obtido.

**Conflicts of interest:** The authors have no conflicts of interest to declare.

**Financing Support:** This work has not received any contribution, grant or scholarship.

**Confidentiality of data:** The authors declare that they have followed the protocols of their work center on the publication of data from patients.

**Protection of human and animal subjects:** The authors declare that the procedures followed were in accordance with the regulations of the relevant clinical research ethics committee and with those of the Code of Ethics of the World Medical Association (Declaration of Helsinki).

**Patients consent:** Obtained.

## REFERENCES

1. Chapman PB, Hauschild A, Robert C, Haanen JB, Ascierto P, Larkin J, et al. Improved survival with vemurafenib in melanoma with BRAF V600E mutation. *N Engl J Med*. 2011;364:2507–16. doi: 10.1056/NEJMoa1103782.
2. Gençler B, Gönül M. Cutaneous side effects of BRAF inhibitors in advanced melanoma: Review of the literature. *Dermatol Res Pract*. 2016;2016:1–6. doi: 10.1155/2016/5361569.
3. Peuvrel L, Quéreux G, Saint-Jean M, Brocard A, Nguyen JM, Khammari A, et al. Profile of vemurafenib-induced severe skin toxicities. *J Eur Acad Dermatol Venereol*. 2016;30:250–7. doi: 10.1111/jdv.13443.
4. Sinha R, Edmonds K, Newton-Bishop JA, Gore ME, Larkin J, Fearfield L. Cutaneous adverse events associated with vemurafenib in patients with metastatic melanoma: practical advice on diagnosis, prevention and management of the main treatment-related skin toxicities. *Br J Dermatol*. 2012;167:987–94. doi: 10.1111/bjd.12010.
5. McArthur GA, Chapman PB, Robert C, Larkin J, Haanen JB, Dummer R, et al. Safety and efficacy of vemurafenib in BRAFV600E and BRAFV600K mutation-positive melanoma (BRIM-3): extended follow-up of a phase 3, randomised, open-label study. *Lancet Oncol*. 2014;15:323–32. doi: 10.1016/S1470-2045(14)70012-9.
6. Sinha R, Lecomwasam K, Purshouse K, Reed J, Middleton MR, Fearfield L. Toxic epidermal necrolysis in a patient receiving vemurafenib for treatment of metastatic malignant melanoma. *Br J Dermatol*. 2014;170:997–9. doi: 10.1111/bjd.12796.
7. Jeudy G, Dalac-Rat S, Bonniaud B, Hervieu A, Petrella T, Collet E, et al. Successful switch to dabrafenib after vemurafenib-induced toxic epidermal necrolysis. *Br J Dermatol*. 2015;172:1454–5. doi: 10.1111/bjd.13522.
8. Wantz M, Spanoudi-Kitrimi I, Lasek A, Lebas D, Quinchon J-F, Modiano P. Necrolyse épidermique toxique au vemurafenib. *Ann Dermatol Vénéréol*. 2014;141:215–8. doi: 10.1016/j.annder.2013.10.054.
9. Lapresta A, Dotor A, González-Herrada C. Toxic epidermal necrolysis induced by vemurafenib. *Actas Dermosifiliogr*. 2015;106:682–3. doi: 10.1016/j.ad.2015.03.008.
10. Arenbergerova M, Mrazova I, Horazdovsky J, Sticova E, Fialova A, Arenberger P. Toxic epidermal necrolysis induced by vemurafenib after nivolumab failure. *J Eur Acad Dermatol Venereol*. 2017;31:e253–4. doi: 10.1111/jdv.14010.
11. Kılıç S, Özkaya E, Baykal C, Vatansever S. Vemurafenib-induced toxic epidermal necrolysis: Is it an emerging side-effect of the drug? *J Eur Acad Dermatol Venereol*. 2017;31:e354–5. doi: 10.1111/jdv.14150.
12. Ling-He Meng JZ, Meng LH, Zhang LT, Yu GX. Cytokines induced skin adverse reactions. *J Clin Exp Dermatol Res*. 2014;5.
13. Guillot B, Blazquez L, Bessis D, Dereure O, Guilhou JJ. A prospective study of cutaneous adverse events induced by low-dose alpha-interferon treatment for malignant melanoma. *Dermatology*. 2004;208:49–54. doi: 10.1159/000075046.